



## Research Article

# Computational and Preclinical Evidence of Anti-ischemic Properties of L-Carnitine-Rich Supplement via Stimulation of Anti-inflammatory and Antioxidant Events in Testicular Torsed Rats

Janet Olayemi Olugbodi <sup>1,2</sup>, Keren Samaila,<sup>2</sup> Bashir Lawal <sup>3,4</sup>,  
Oluchukwu Ogechukwu Anunobi,<sup>2</sup> Roua S. Baty,<sup>5</sup> Omotayo Babatunde Ilesanmi <sup>6</sup>,  
and Gaber El-Saber Batiha<sup>7</sup>

<sup>1</sup>Department of Medicine, Emory University School of Medicine, Atlanta, USA

<sup>2</sup>Department of Biochemistry, Bingham University, Abuja-Keffi Expressway Road, Karu, Nigeria

<sup>3</sup>PhD Program for Cancer Molecular Biology and Drug Discovery, College of Medical Science and Technology, Taipei Medical University and Academia Sinica, Taipei 11031, Taiwan

<sup>4</sup>Graduate Institute for Cancer Biology & Drug Discovery, College of Medical Science and Technology, Taipei Medical University, Taipei 11031, Taiwan

<sup>5</sup>Department of Biotechnology, College of Science, Taif University, P.O. Box 11099, Taif 21944, Saudi Arabia

<sup>6</sup>Department of Biochemistry, Faculty of Science, Federal University Otuoke, Ogbia, Bayelsa State, Nigeria

<sup>7</sup>Department of Pharmacology and Therapeutics, Faculty of Veterinary Medicine, Damanshour University, Damanshour 22511, AlBeheira, Egypt

Correspondence should be addressed to Janet Olayemi Olugbodi; [janetolayemi@binghamuni.edu.ng](mailto:janetolayemi@binghamuni.edu.ng) and Bashir Lawal; [bashirlawal12@gmail.com](mailto:bashirlawal12@gmail.com)

Received 2 March 2021; Revised 21 May 2021; Accepted 14 June 2021; Published 5 July 2021

Academic Editor: Margaret H Hastings

Copyright © 2021 Janet Olayemi Olugbodi et al. This is an open access article distributed under the Creative Commons Attribution License, which permits unrestricted use, distribution, and reproduction in any medium, provided the original work is properly cited.

Ischemia-reperfusion injury is a urological emergency condition that could lead to necrosis, testicular damage subfertility, and infertility. The purpose of this study was to identify changes taking place in the rat testis at short-term (4 hr) as well as long-term (7 days) reperfusion following testicular torsion and to evaluate the effects of Proxeed Plus (PP), L-carnitine-rich antioxidant supplement, on preventing these changes using the biochemical parameters and histopathology. Thirty adult male rats were divided into five groups: in groups, 1-4 testicular ischemia was achieved by rotating the left testis 720° clockwise for 4 h and dividing into the sham, torsion/detorsion (T/D), T/D+1000 mg/kg BW PP, and T/D+5000 mg/kg BW PP groups, respectively. PP was administered intraperitoneally 30 min before detorsion while group 5 served as the normal control. All rats were sacrificed 4 h after detorsion. The same experimental design was set up, and animals were sacrificed after 7 days of detorsion. The testicular levels of human cyclooxygenase-2; tumor necrosis factor; interleukins-1 $\beta$ , 6, and 10; hydrogen peroxide; malonaldehyde; superoxide dismutase; catalase; glutathione transferase; glutathione peroxidase; glutathione reductase; and histopathological damage were evaluated. Our results revealed that rats in the torsion/detorsion group exhibited elevated testicular levels of oxidative markers and proinflammatory cytokines, low levels of antioxidant enzymes, and severe histological alterations relative to the control and sham groups. Treatments with 1000 and 5000 mg/kg BW of PP for 4 hr and 7 days significantly ( $p < 0.05$ ) decreased the levels of the proinflammatory and oxidative markers while increasing the spermatogenesis, testicular levels of antioxidant enzymes, and anti-inflammatory cytokine (IL-10) in a dose-dependent manner. This suggested that PP exhibited anti-inflammatory and antioxidant activities against I/R testes thus serving as an effective supplement to protect against testicular assault.

## 1. Introduction

Testicular torsion (TT) is a serious medical and surgical crisis, which occurs due to rotation and abnormal twisting of the spermatic cord of the testis or the mesorchium [1]. The degree and length of torsion are vital determinants of testicular damage [1, 2]; thus, prompt diagnosis and early medical intervention are necessary for managing this condition. It is not a frequently encountered condition (1 out of 4000 males) and occurs mostly in males under the age of 25 years [3]. However, it is considered a dangerous pathological condition that causes a decreased flow of blood to the testes causing scrotal pain and finally leading to testicular atrophy [4, 5]. This interrupted blood flow leads to ischemia during which ATP gets depleted while degradation products such as hypoxanthine increase, causing damages to metabolically active tissues [6]. However, following the acute ischemia, the tissues undergo reperfusion during which the tissue blood flow is being attenuated, causing more damaging effects than that induced by ischemia [7].

The reactive oxygen species (ROS) such as superoxide anions, hydrogen peroxide, and hydroxyl radicals have been implicated in the pathogenesis of testicular ischemia/reperfusion (I/R) injury [8, 9], and several antioxidant therapies have been experimentally used to reverse the antioxidant-induced testicular damage [10, 11]. In fact, ROS constitutes the basic pathophysiological processes of the I/R injury in the testis and other tissues such as the brain, myocardium, and kidneys [9, 12]. The restoration of blood flow during ischemia-reperfusion (I/R) injury triggers a chain of reactions that lead to the generation of reactive oxygen species (ROS) by the injured testicular cells and endothelial cells in the ischemic zone, as well as neutrophils that enter the ischemic zone, and become activated on reperfusion [13–15]. This generation of reactive oxygen species (ROS) can cause testicular oxidative cell and tissue damage by the destruction of the integrity of the cell membrane, induction of lipid peroxidation, protein denaturation, and DNA damage [16, 17]. Serum malondialdehyde (MDA) concentration in patients with testis torsion has been identified as a reliable marker of lipid peroxidation and tissue damage [18, 19]. However, time course, short- and long-term testis reperfusion damages, and time course therapeutic strategies have been reported [18, 20].

Furthermore, when a tissue suffers from ischemia-reperfusion, inflammatory mediators like prostaglandin E<sub>2</sub> (PGE<sub>2</sub>) and nitric oxide (NO) are produced through the activations of cyclooxygenase-2 (Cox-2) and inducible NO synthase (iNOS), respectively [14]; also, proinflammatory cytokines like interleukin-6 (IL-6), interleukin-1 $\beta$  (IL-1 $\beta$ ), and tumor necrosis factor (TNF- $\alpha$ ) are highly produced [21]. These proinflammatory cytokines trigger the productions of ROS, which stimulates neutrophil infiltration and results in ischemic injury [12]. Therefore, inflammatory mediators and proinflammatory markers play important roles in oxidative stress-induced I/R injury [22].

The testes contain some natural antioxidants such as vitamins, thioredoxin, glutathione, and superoxide dismutase [23] that play a vital role in protecting the testes against oxidative damage during assaults. However, relatively low

levels of these natural antioxidants in the cytoplasm and high levels of membrane polyunsaturated fatty acids make spermatozoa susceptible to ROS attack from lipid peroxidation [23, 24]. A curative approach that attenuates the production of these inflammatory markers and free radicals could salvage the testis from impairment during I/R injury. Several anti-inflammatory and antioxidant free radical scavengers have been used to prevent I/R injury in tissues.

L-carnitine (LC) plays a pivotal role in cellular energetic metabolism, acting as a shuttle of the activated long-chain fatty acids (acyl-CoA) into the mitochondria, where beta-oxidation takes place [25, 26]. L-carnitine is found at a high level in epididymal fluid due to an active secretory mechanism [27]; in addition, high levels of L-carnitine in epididymal lumen and L-acetylcarnitine (LAC) in sperm cells have been implicated in the initiation of sperm motility [28, 29]. Clinical studies have also indicated that oral administration of L-carnitine improves sperm quality of patients with idiopathic asthenozoospermia [30] and have also been used for the treatment of idiopathic and varicocele-associated oligoasthenospermia [31]. In addition, Lenzi et al. [32] successfully used L-carnitine in idiopathic infertile males while another study demonstrated that a combination of L-carnitine+acetyl-L-carnitine increased sperm count in patients with echographic features of genital inflammation [33]. Decreased total L-carnitine levels may be associated with hyperandrogenism and/or insulin resistance in nonobese women with polycystic ovary syndrome (PCOS) [34].

Proxceed Plus is a lemon flavor carnitine-based supplement specially formulated to support sperm health and boost a man's reproductive ability. It is a composite of L-carnitine, acetyl-L-carnitine, zinc, fumarate, CoQ10, folic acid, fructose, vitamin C, and vitamin B12 [35]. These ingredients are known to play a vital function in spermatozoa by optimizing energy and hormonal metabolism, maintaining sperm health, and exhibiting antioxidant activities [24, 36–38]. A recent randomized clinical study involving over 100 oligoasthenozoospermia men reported a significant increase in progressive sperm motility and total sperm count in groups treated with Proxceed Plus for 6 months compared to the placebo [39]. Another clinical trial with 175 idiopathic oligoasthenozoospermia men who could not impregnate their partners revealed that Proxceed Plus treatments for 3 and 6 months significantly improve the sperm volume and progressive motility compared to the baseline [40]. Other biological activities of Proxceed Plus including neuroprotection [41] have been reported. In the present study, we demonstrated the beneficial effects of Proxceed Plus on attenuating the inflammatory condition and oxidative stress induced by ischemia-reperfusion of the testes in male rats.

## 2. Materials and Methods

*2.1. Test Supplement (Proxceed Plus), Chemicals, and Assay Kits.* The test supplement (Proxceed Plus) was obtained from Sigma-Tau Health Science, Utrecht, the Netherlands. Enzyme-linked immunosorbent assay kits are Rat Interleukin-1 ELISA Kit and Rat Tumor Necrosis Factor ELISA Kit, respectively, Shanghai LZ, China. The Glutathione Assay Kit and Lipid

Peroxidation (MDA) Assay Kit were from Sigma-Aldrich, USA. The Cox activity assay kit was from Cayman, Ann Arbor, MI, USA. Ketamine was obtained from Ketalar, Pfizer Pharm GMBH, Germany. All other chemicals were from Sigma-Aldrich Co., St. Louis, MO, USA.

**2.2. Experimental Animals.** Fifty (50) male albino rats weighing  $126.45 \pm 3.97$  g were procured from the animal farm of Bingham University. The animals were maintained under standard laboratory conditions with access to commercial feed pellets (growers) and water ad libitum. Animal handling and experimentations complied with the principles governing the use of laboratory animals as laid out by the international standard set by the UK Animals (Scientific Procedures) Act, 1986 and associated guidelines, the European Communities' council directive of 24 November 1986 (86/609/EEC), and the National Institutes of Health *Guide for the Care and Use of Laboratory Animals* (NIH Publication No. 8023, revised 1978). All experimental protocols were approved by Bingham University, Committee on Ethics for Medical and Scientific Research (BHU/REC/19/A005), and principles governing the use of laboratory animals as laid out by the Bingham University, Committee on Ethics for Medical and Scientific Research, were duly observed.

**2.3. Experimental Design and Animal Grouping.** Time course (short- and long-term) testicular reperfusion damages have been reported [18, 20]; for these reasons, two experimental protocols were designed. The first protocol involved 5 experimental groups (5 rats per group) and was designed to identify changes taking place in the rat testis at short-term (4 hr) reperfusion following testicular torsion and to evaluate the effects of Proxeed Plus (PP).

Group 1: control group that received 2 ml/kg BW normal saline

Group 2: sham group

Group 3: torsion/detorsion (T/D)

Group 4: T/D+1000 mg/kg BW PP

Group 5: T/D+5000 mg/kg BW PP

In groups 4 and 5, Proxeed Plus was administered intraperitoneally 30 min before detorsion. 1000 mg/kg BW (low dose) and 5000 mg/kg BW (high dose) of PP were selected based on the recommended therapeutic regime of Proxeed Plus and also based on our previous toxicity study indicating that PP was safe and devoid of adverse effect even at a high dose of 5000 mg/kg BW. All rats were sacrificed 4 h after detorsion. However, in order to identify the changes taking place in the rat testis after long-term (7 days) reperfusion following testicular torsion and to evaluate the effects of Proxeed Plus (PP), the second protocol was designed with 5 experimental groups as described in the first protocol; however, all animals were sacrificed after 7 days of detorsion. The surgical procedure was carried out based on previous experimental studies [42, 43]. In brief, the rats were anesthetized using intraperitoneal injections of 50 mg/kg BW of ketamine hydrochloride and 10 mg/kg BW of xylazine. Through a longitudinal scrotal incision, the left testis of the animals in each group was exposed and dissected. Afterward, the torsion of the left testis was induced by a 720° counter-

clockwise rotation. One hour later, the testis was counterrotated to the natural position and was inserted into the scrotum. Then, the skin incision was sutured (4-0 nonabsorbable), and animals were kept until harvesting time. In the sham animals, only surgical stress was applied by immediately retracting and replacing the spermatic cord.

**2.4. Collection and Preparation of Organ.** The testis was carefully harvested and homogenized in 0.25 M in 0.1 M phosphate buffer pH 7.4 using a Teflon homogenizer, and the homogenate was centrifuged at 3,000 r.p.m. for 15 minutes [44, 45], after which the supernatant was transferred into plain sample bottles for analysis.

**2.5. Estimation of Testicular Levels of Prooxidative Molecules and Antioxidant Enzymes**

**2.5.1. Lipid Peroxidation.** The testicular concentrations of malonaldehyde (MDA) as an index of lipid peroxidation were estimated spectrophotometrically by the thiobarbituric acid-reactive substance (TBARS) methods as described by Varshney and Kale [46]. Briefly, 0.4 ml of the sample was mixed with 1.6 ml of Tris KCl buffer (0.15 M) to which 30% TCA (0.5 ml) was added. Then, 0.5 ml of 52 mM TBA was added and incubated in a water bath (80°C) for 45 min; this was followed by ice cooling centrifugation (3,000 rpm) at room temperature for 10 min. The supernatant was separated, and the absorbance was measured against the reference blank of distilled water at 531.8 nm.

**2.5.2. Proteins and  $H_2O_2$ .** The testicular proteins and  $H_2O_2$  concentrations were assessed by the spectrophotometric methods of Gornall et al. [47] and Koroliuk et al. [48], respectively. Briefly, 10  $\mu$ l of the sample was incubated for 10 min with 100  $\mu$ mol/ml  $H_2O_2$  in 0.05 mmol/l Tris-HCl buffer (pH = 7). The yellow complex of ammonium molybdate ( $(NH_4)_2MoO_4$ ) and  $H_2O_2$  was monitored at 410 nm after terminating the reaction with 50  $\mu$ l of 4%  $(NH_4)_2MoO_4$ .

**2.5.3. Catalase (CAT).** The testicular activities of catalase were evaluated using a spectrophotometer by monitoring  $H_2O_2$  clearance as described by Sinha [49]. The reaction mixture contained 2.9 ml of 10 mM  $H_2O_2$  in 50  $\mu$ M potassium phosphate buffer (pH 7) followed by 0.1 ml of tissue homogenate. The rate of decrease in the absorbance at 240 nm was recorded for 3 min. The results were expressed as  $\mu$ mol  $H_2O_2$ /min/mg of protein.

**2.5.4. Superoxide Dismutase (SOD).** The superoxide dismutase activity was estimated based on the principle of inhibition of autooxidation of epinephrine at 30°C and pH 10.2 as described by Misra and Fridovich [50]. Briefly, 25  $\mu$ l of the homogenate was mixed with 0.1 mM epinephrine in carbonate buffer (pH 10.2) in a total volume of 1 ml, and the formation of adrenochrome was measured at 295 nm using a spectrophotometer. The SOD activity (U/mg of protein) was calculated by using the standard plot.

**2.5.5. Glutathione Reductase (GSH).** The activity of glutathione reductase was determined as described by Smith et al. [51] with small modifications. The reaction mixture in a total

of 3 ml consists of 2.9 ml of 5,5-dithiobis(2-nitrobenzoic acid) prepared in potassium phosphate buffer (0.1 M, pH 7.4), and 0.1 ml of tissue homogenate was incubated for 15 min at 37°C, and the absorbance was measured at 412 nm. The results were expressed as  $\mu\text{mol}/\text{mg}$  protein.

**2.5.6. Glutathione Peroxidase (GPx).** Glutathione peroxidase (GPx) activities were estimated using the spectrophotometric methods as described by Hu and Dillard [52]. Glutathione peroxidase (GPx) catalyzed the oxidation of glutathione by cumene hydroperoxide. In the presence of NADPH and glutathione reductase, the oxidized glutathione was immediately converted to the reduced form with concomitant oxidation of NADPH to  $\text{NADP}^+$  [53]. An aliquot (10  $\mu\text{l}$ ) of the tissue homogenate was mixed with 500  $\mu\text{l}$  mixed reagent and 20  $\mu\text{l}$  cumene hydroperoxide. The absorbance was measured at 340 nm.

**2.5.7. Glutathione S-Transferase (GST).** Glutathione S-transferase (GST) activities were estimated using a spectrophotometer as described by Habig et al. [54]. The reaction mixture in a volume of 3 ml contained 2.4 ml of 0.3 M potassium phosphate buffer (pH 6.9), 0.1 mL of 30 mM 1-chloro-2,4-dinitrobenzene (CDNB), 0.1 ml of 30 mM GSH, and the enzyme source. The reaction was initiated by glutathione. The absorbance was followed for 5 min at 340 nm against a reagent blank.

**2.6. Estimation of Testicular Levels of Inflammatory Markers.** The testicular levels of tumor necrosis factor- $\alpha$  (TNF- $\alpha$ ), cyclooxygenase-2 (Cox-2) activity, interleukin-1 $\beta$  (IL-1 $\beta$ ), interleukin-6 (IL-6), and interleukin-10 (IL-10) levels were measured in duplicate by ELISA kits as described previously [55] and by following the manufacturer's directives.

**2.7. Histopathological Evaluation of Testis.** The testes of rats were fixed in 10% formalin and processed for histology using standard procedures. Further histological preparations were carried out as described by Igwebuike and Eze [56] and stained with hematoxylin and eosin for light microscopy.

**2.8. Molecular Docking.** The chemical structure of our ligand drug (L-carnitine) was retrieved as mol file format from the PubChem database. The ligand was converted into PDB format using Pymol and converted into PDBQT format using AutoDock Tools 1.5.6. All the protein targets (receptors), human cyclooxygenase-2 (PDB = 5kir), tumor necrosis factor (PDB = 1TNF), human interleukin-6 (PDB = 1ALU), and human interleukin-1 beta (PDB = 9ILB) were retrieved as PDB format file from Protein Data Bank and subsequently converted to PDBQT format. The ligands were prepared for docking by deletion of  $\text{H}_2\text{O}$  molecules, adjustment of polar hydrogen, and addition of Kollman charges. The molecular docking was performed using AutoDock Vina with all parameters set as default, and all bonds in the ligand are rotated freely, considering the receptor as rigid [57–59]. A grid box of  $40 \text{ \AA} \times 40 \text{ \AA} \times 40 \text{ \AA}$  was generated on defined binding site residues of the ligand. The docked ligand-receptor complex was visualized and analyzed using Pymol.

**2.9. Bioinformatics Study.** We used the testicular necrosis bioinformatics tools (<https://www.novusbio.com/diseases/testicular-necrosis>) to explore the genes, diseases, and pathways that are strongly associated with testicular torsion and necrosis.

**2.10. Data Analysis.** Data were expressed as the mean  $\pm$  SD of six determinations. The analysis was performed using the SPSS statistical package for Windows (version 21.0; SPSS Inc, Chicago). Results were subjected to ANOVA followed by DMRT. Statistically significant was considered at  $p < 0.05$ .

### 3. Results

**3.1. CAT/SOD/CASP3/TNF/GPx Is a Regulatory Signature of Testicular Torsion and Is Associated with Testicular Necrosis.** Testicular torsion occurs when there is a mechanical twisting of the spermatic cord. Using the testicular necrosis bioinformatics tools (<https://www.novusbio.com/diseases/testicular-necrosis>), we found that there is a strong association between testicular necrosis and spermatic cord torsion, testicular diseases, testicular pain, atrophy, hernia, and inguinal. In addition, we found that spermatogenesis is an important pathway related to testicular torsion. Furthermore, we identified catalase, superoxide dismutase, caspase 3, TNF, glutathione peroxidase, and MSTD as the most important regulatory genes involved in spermatic cord torsion (Figure 1).

**3.2. Proxeed Plus Exhibits Anti-Inflammatory Activities via Downregulation of TNF- $\alpha$ /IL-6/IL-1 $\beta$ /Cox-2 in Testicular Reperfused Rats.** The torsion/detorsion rats displayed elevated levels of testicular TNF- $\alpha$ , interleukin-6 (IL-6), interleukin-1 $\beta$  (IL-1 $\beta$ ), and Cox-2 but low level of interleukin-10 (IL-10) as compared with the control rats ( $p < 0.05$ ). The sham group also exhibited a slight increase in the levels of inflammatory markers but lower compared with the T/D groups. Treatments of T/D with 1000 and 5000 mg/kg BW of Proxeed Plus for 4 hr and 7 days produce a significant and dose-dependent decrease to the levels of the inflammatory markers. The 7 days' treatment displays higher modulation of the inflammatory markers than the 4 hr treatments. The level of Cox-2 in T/D rats following 7 days' treatments with 1000 and 5000 mg/kg BW of Proxeed Plus was significantly lower than that of the control groups (Figure 2).

**3.3. Proxeed Plus Prevents Reperfusion-Induced Oxidative Stress by Decreasing the Generation of  $\text{H}_2\text{O}_2$  and MDA in Testicular Reperfused Rats.** Evaluation of antioxidant markers following testicular torsion/detorsion indicated that rats in the torsion/detorsion groups had significantly ( $p < 0.05$ ) high levels of  $\text{H}_2\text{O}_2$  and MDA than the control group and other experimental groups. Treatments of T/D rats with 1000 and 5000 mg/kg BW of Proxeed Plus for 4 hr and 7 days produce significant decreases in the levels of  $\text{H}_2\text{O}_2$  and MDA relative to the untreated (T/D) group. Rats treated with 5000 mg/kg BW restored the normal levels of  $\text{H}_2\text{O}_2$  and MDA. Furthermore, the reduction in the levels of total proteins observed in T/D groups was significantly reversed by PP treatments (Figure 3).



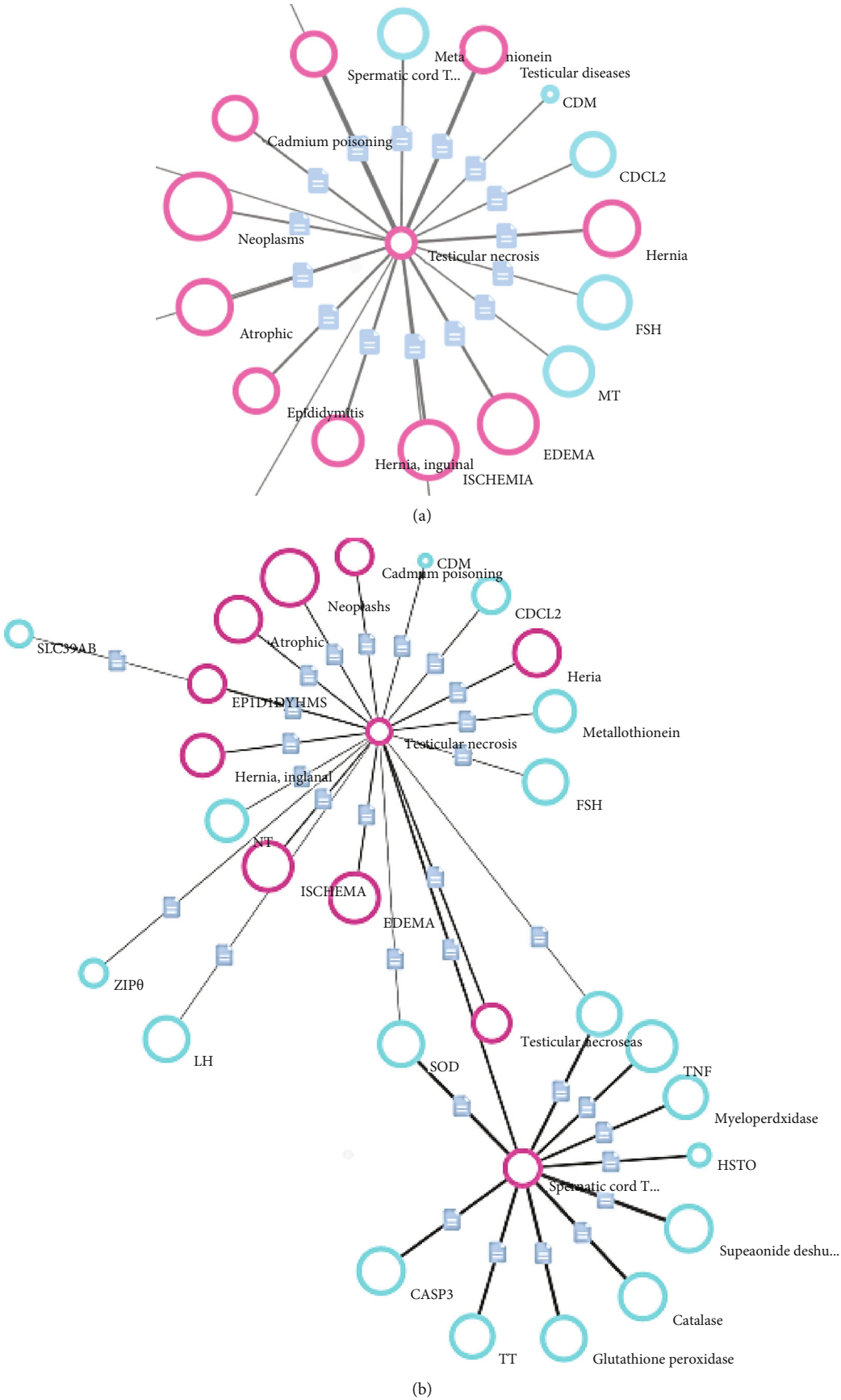


FIGURE 1: Genes, diseases, and pathways associated with testicular torsion and necrosis.

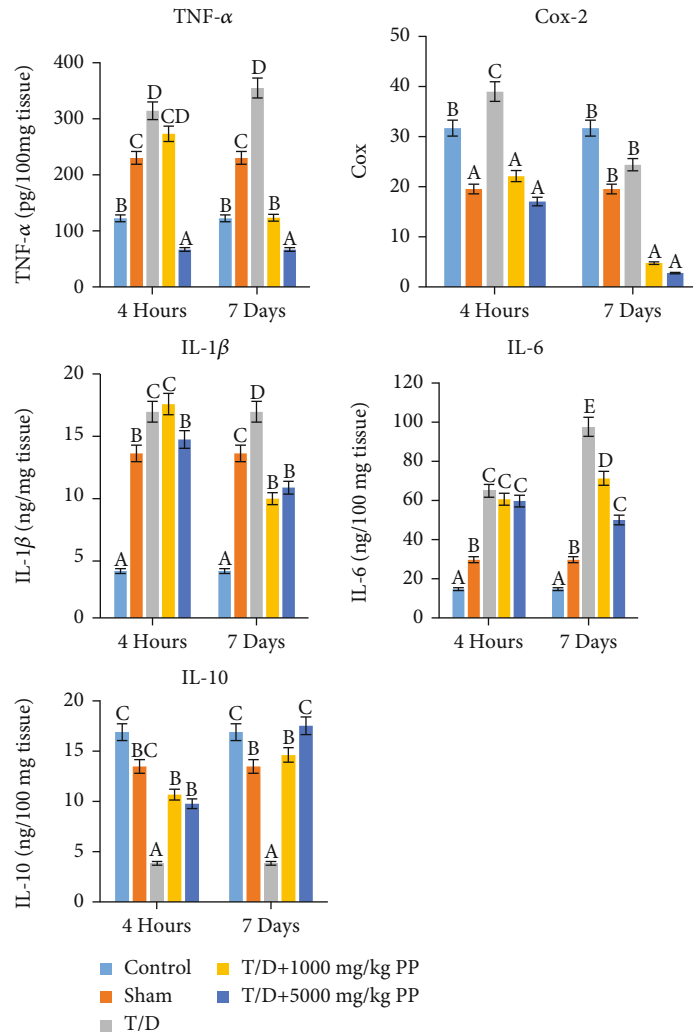


FIGURE 2: Proxeed Plus elicits anti-inflammatory response in torsion/detorsion rat testis. Tumor necrosis factor-alpha (TNF- $\alpha$ ), cyclooxygenase- (Cox-) 2 activity, interleukin-1 $\beta$  (IL-1 $\beta$ ), interleukin-6 (IL-6), and interleukin-10 (IL-10) level. Each bar represents the mean  $\pm$  SD of 6 determinations. Bars with different superscript alphabets are significantly different ( $p < 0.05$ ). The high significant levels of the parameters were in the order of a < b < c. Bars with superscript alphabet "a" are significantly lower than bars with superscript alphabet "b" while bars with superscript "b" are lower than bars with superscript alphabet "c" at  $p < 0.05$ .

**3.4. Proxeed Plus Enhances the Antioxidant Status of Testicular Reperfused Rat via Induction of CAT/GST/SOD/GPx Activities.** The antioxidant enzymes evaluated after 4 hr and 7 days of torsion/detorsion indicated that rats in the torsion/detorsion groups had significantly ( $p < 0.05$ ) low levels of antioxidant enzymes, catalase (CAT), glutathione reductase (RG), glutathione S-transferase (GST), superoxide dismutase (SOD, and glutathione peroxidase (GPx) than the control group and other experimental groups. Treatments of T/D rats with 1000 and 5000 mg/kg BW of Proxeed Plus for 4 hr and 7 days produce significant and dose-dependent increases in the levels of the antioxidant's enzymes. Furthermore, Proxeed Plus treatments increase the levels of catalase, superoxide dismutase, glutathione reductase, and glutathione S-transferase than the levels in the control rats (Figure 4).

**3.5. Proxeed Plus Ameliorates Reperfusion-Induced Histological Impairments in Rats.** Histological examinations of the testes

revealed normal testicular architecture with normal germ layer and maturation stages of control rats. Similarly, the sham group shows a normal histological picture of the testes. The torsion/detorsion group shows very poor architecture with several degenerated seminiferous tubules and degenerated germinal epithelial cells. Also, testis of rats treated with PP (1000 mg/kg) at 4 hr had similar histoarchitecture with the T/D rats while that of 5000 mg/kg BW has moderately normal spermatogonia cells and Sertoli cells and few seminiferous tubules. However, 7 days' treatment (1000 mg/kg) exhibited poor architecture, in which seminiferous tubules show tubular vacuolation and cessation of spermatogenesis while testes of rats under 7 days' treatments (5000 mg/kg) have moderately normal testicular architecture with normal Sertoli cells and several seminiferous tubules (Figures 5–8).

**3.6. Proxeed Plus Enhances the Spermatogenesis Ability of the Testicular Reperfused Rats.** Testicular ischemia-reperfusion

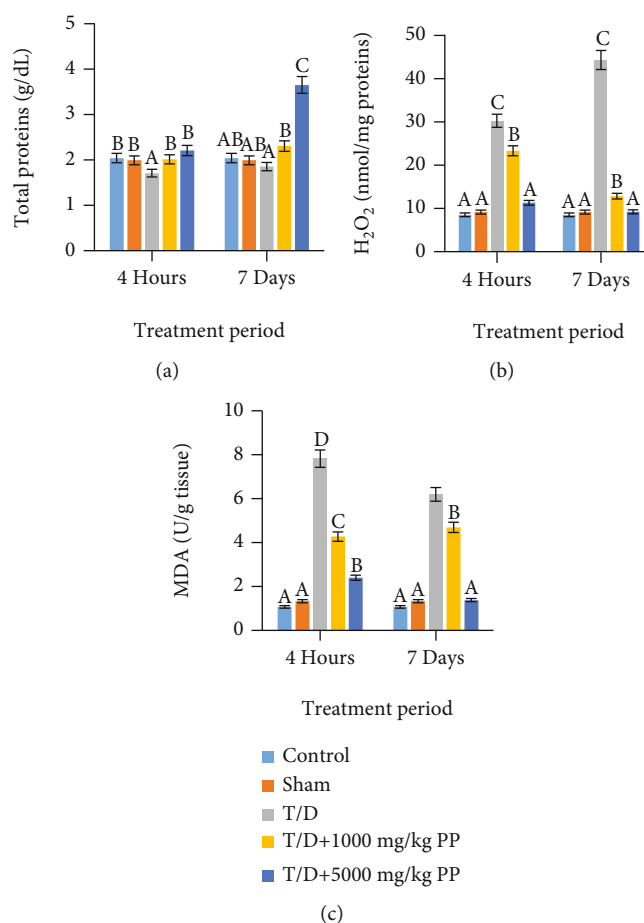


FIGURE 3: Proxeed Plus prevents torsion/detorsion-induced free radical generation and lipid peroxidation in rat testis: (a) total proteins; (b) hydrogen peroxide ( $H_2O_2$ ); (c) malonaldehyde (MDA). Each bar represents the mean  $\pm$  SD of 6 determinations. Bars with different superscript alphabets are significantly different ( $p < 0.05$ ). The high significant levels of the parameters were in the order of  $a < b < c$ . Bars with superscript alphabet "a" are significantly lower than bars with superscript alphabet "b" while bars with superscript "b" are lower than bars with superscript alphabet "c" at  $p < 0.05$ .

of male rats induces spermatogenic impairments in rats as evidenced by significant ( $p < 0.05$ ) decreases in all sperm velocity parameters (ALH, beat cross frequency, linearity, and straightness), sperm kinematics (straight-line velocity, curvilinear velocity, and average path velocity), and sperm motility (total motility, progressive motility, mean move angle degree, and wobble), while the sperm nonprogressive motility and immobility increase in the T/D group (Table 1). Interestingly, treatments with Proxeed Plus (1000 and 5000 mg/kg BW) exhibited significant ( $p < 0.05$ ) and dose-dependent increases in parametric measures of sperm velocity, kinematics, and progressive motilities while decreasing sperm nonprogressive motility and immobility (Table 1).

**3.7. Molecular Docking Analysis Revealed That L-Carnitine Component of Proxeed Plus Formed Stable Interaction with the Binding Cavity of IL-6/IL-1 $\beta$ /Cox-2.** Docking simulation of L-carnitine with IL-1 $\beta$ , IL-6, and Cox-2 revealed binding affinities of -5.5, -5.9, and -6.8 kcal/mol. The L-carnitine backbone interacts with IL-1 $\beta$  by H-bonding with GLU64 residue of the binding pocket while it interacts with the binding pocket of IL-6 and Cox-2 by hydrogen bonding with

ARG 104 and ASN 144 residue, respectively. The binding distance between the ligand and IL-1 $\beta$ , IL-6, and Cox-2 was 4.9, 2.2, and 3.1 Å, respectively (Figure 9 and Table 2).

#### 4. Discussion

Our study pioneered the report of testicular-protective effects of Proxeed Plus against T/D-induced testis impairments. Ischemia-reperfusion provokes an inflammatory immune response and promotes tissue oxidative stress-induced damages [60]. Overproduction of inflammatory mediators, such as prostaglandin E2 (PGE2) through the activations of cyclooxygenase-2 (Cox-2), and proinflammatory cytokines, including IL-1 $\beta$ , TNF- $\alpha$ , and IL-6, has been implicated in diseases associated with inflammatory response [21, 22]. Furthermore, elevated levels of cytokine in serum and liver, lung, kidney, gut, brain, and heart have been documented during organ T/D [33–37]. Consistently, the present study showed elevated levels of testicular TNF- $\alpha$ , interleukin-6 (IL-6), interleukin-1 $\beta$  (IL-1 $\beta$ ), and Cox-2 but decreased interleukin-10 (IL-10) in rats that underwent T/D. The elevation of such proinflammatory mediators in T/D rats may be a

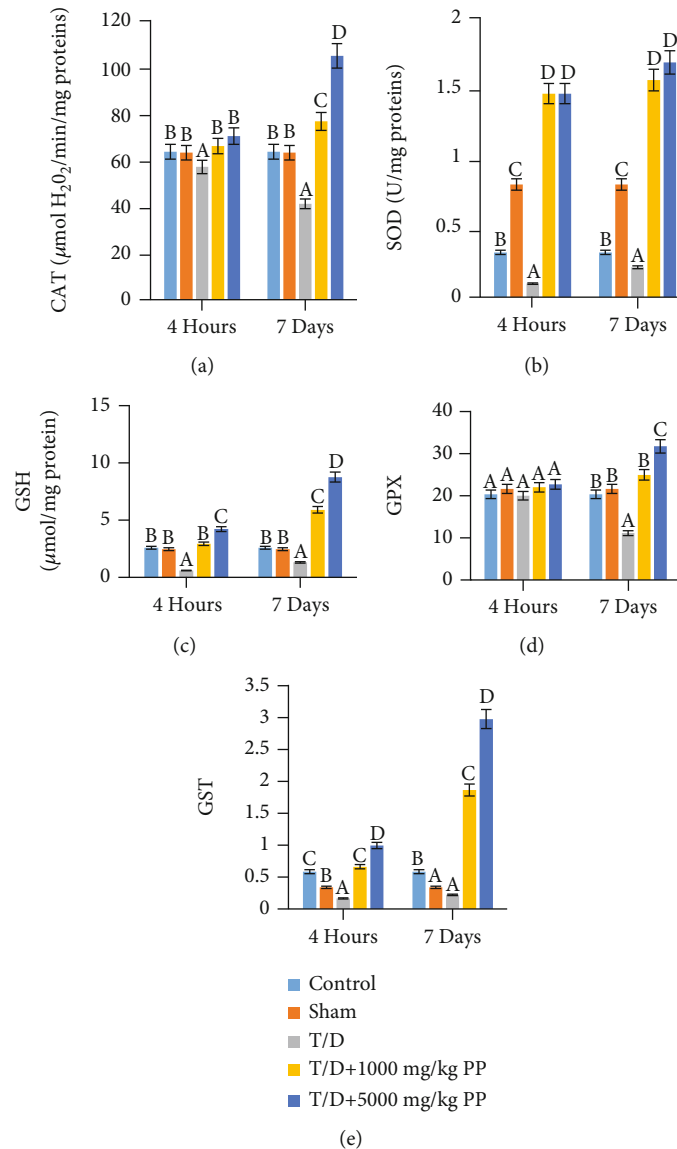


FIGURE 4: Proxeed Plus enhances antioxidant system and prevents torsion/detorsion-induced oxidative impairment in rat testis: (a) catalase (CAT); (b) superoxide dismutase (SOD); (c) glutathione reductase (GSH); (d) glutathione peroxidase (GPx); (e) glutathione S-transferase (GST). Each bar represents the mean  $\pm$  SD of 6 determinations. Bars with different superscript alphabets are significantly different ( $p < 0.05$ ). The high significant levels of the parameters were in the order of  $a < b < c$ . Bars with superscript alphabet "a" are significantly lower than bars with superscript alphabet "b" while bars with superscript alphabet "b" are lower than bars with superscript alphabet "c" at  $p < 0.05$ .

mechanism by which ischemia-reperfusion accelerates testicular distortion and sterility in man.

Fortunately, treatment of T/D rats with PP exhibited remarkable anti-inflammatory effects by significantly reducing the testicular concentrations of the inflammatory mediators (Cox enzyme) and proinflammatory markers TNF- $\alpha$ , interleukin-6 (IL-6), and interleukin-1 $\beta$  (IL-1 $\beta$ ) and increasing the levels of interleukin-10 (IL-10). IL-10 is a T helper 2 type cytokine that inhibits the generations of the proinflammatory cytokines, including IL-1, IL-6, and TNF- $\alpha$  [61]. It exhibited its inhibitory effects by upregulating the generation of soluble TNF- $\alpha$  and IL-1 receptor antagonist [62] thus reducing the levels of proinflammatory cytokines and subsequently attenuating inflammation-induced free radical

generations and oxidative stress [62]. Thus, treatments with PP could be considered a good curative approach to salvage the testis from impairment against T/D-induced inflammatory response. Consistent with the results obtained in the present study, previous studies also reported that treatments of rats with vitamin supplements exhibited an anti-inflammatory effect via inhibition of PGE2 production and Cox enzyme [63, 64].

Oxidative stress and an imbalance between the generation of prooxidant and antioxidant systems have been associated with several organ abnormalities [65–67] and implicated in ischemia-reperfusion-induced testicular impairments [44]. The increased ROS generation leads to oxidative stress and activates apoptosis and increased DNA damage. Therefore,



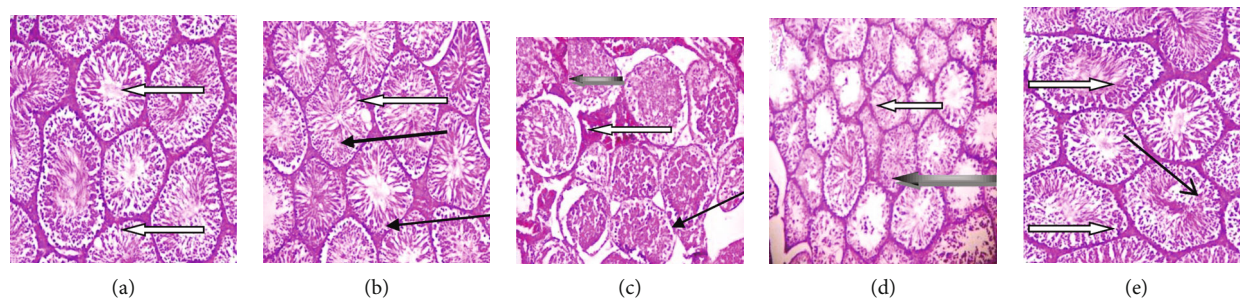


FIGURE 5: Photomicrographs of testis sections stained with hematoxylin and eosin after administration of Proxeed Plus to rats for 4 hours: (a) control group showing normal testicular architecture, the lumen appears normal with presence of spermatozoa (white arrow); (b) sham group showing normal testicular architecture, the lumen appears normal with presence of spermatozoa (white arrow), the interstitial spaces show normal Leydig cells (slender arrow) and mild vascular congestion (black arrow); (c) T/D group showing very poor architecture, severe degeneration of seminiferous tubules (slender arrow), these tubules are fibrotic and show thickened propria (white arrow), they exhibit degenerated germinal epithelial cells and necrosis (black arrow); (d) posttreatment with 1000 mg/kg Proxeed Plus after TD showing interstitial spaces with normal Leydig cells (black arrow), presence of spermatozoa in the lumen (white arrow); (e) posttreatment with 5000 mg/kg Proxeed Plus after TD showing several normal testicular architecture, interstitial spaces with normal Leydig cells (slender arrow), the lumen appears normal with presence of spermatozoa (white arrow). Magnification  $\times 100$ .

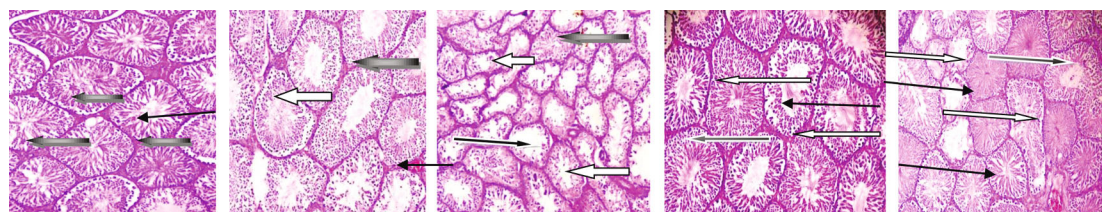


FIGURE 6: Photomicrographs of testis sections stained with hematoxylin and eosin after administration of Proxeed Plus to rats after 7 days: (a) control group showing normal testicular architecture, the lumen appears normal with presence of spermatozoa (slender arrow), normal seminiferous tubules with normal germ cell layer (black arrow). (b) Sham group showing moderately normal testicular architecture, the lumen appears normal with presence of spermatozoa (white arrow), germ cell layer with marked maturation arrest (slender arrow). The interstitial spaces show normal Leydig cells (black arrow); (c) T/D group showing very poor architecture, degenerated and sloughed germinal epithelial cells and obvious maturation arrest (black arrow), and severe vascular congestion (white arrow), generalized and severe degeneration of seminiferous tubules (slender black arrow); (d) posttreatment with 1000 mg/kg Proxeed Plus after TD showing normal Leydig cells (slender arrow), lumen with presence of spermatozoa (white arrow); (e) 5000 mg/kg Proxeed Plus after TD showing normal testicular architecture, the lumen appears normal with presence of spermatozoa (white arrow), normal seminiferous tubules with normal germ cell layer and maturation stages (slender arrow). Magnification  $\times 100$ .

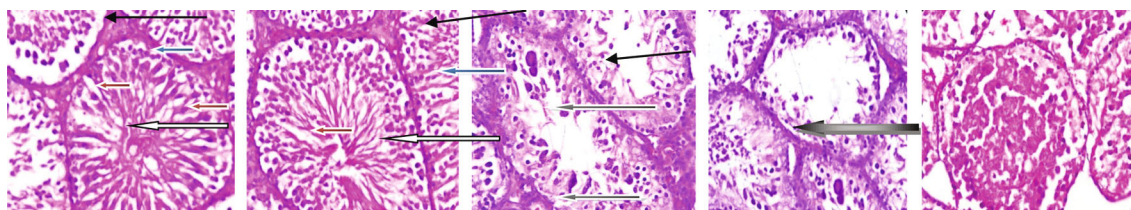


FIGURE 7: Photomicrographs of testis sections stained with hematoxylin and eosin after administration of Proxeed Plus to rats after 4 hours: (a) control group showing normal testicular architecture with seminiferous tubules having normal germ cell layer (slender arrow) and normal maturation stages, there are normal spermatogonia cell (blue arrow) and normal Sertoli cells (red arrow), the lumen appears normal with presence of spermatozoa (white arrow). The interstitial spaces show normal Leydig cells (slender arrow). (b) Sham group showing normal testicular architecture, with normal germ cell layer (slender arrow) and normal maturation stages, there are normal spermatogonia cell (blue arrow) and normal Sertoli cells (red arrow), the lumen appears normal with presence of spermatozoa (white arrow). The interstitial spaces show normal Leydig cells (slender arrow). (c) T/D group very poor architecture, degenerated and sloughed germinal epithelial cells (black arrow), severe degeneration of seminiferous tubules with fibrotic and thickened propria and necrosis (black arrow). (d) 1000 mg/kg Proxeed Plus after TD. The interstitial spaces show normal Leydig cells (slender arrow) normal lumen with presence of spermatozoa (white arrow). (e) 5000 mg/kg Proxeed Plus after TD showing several normal testicular architecture, seminiferous tubules with germ cells and lumen maturation stages (black arrow). Magnification  $\times 400$ .

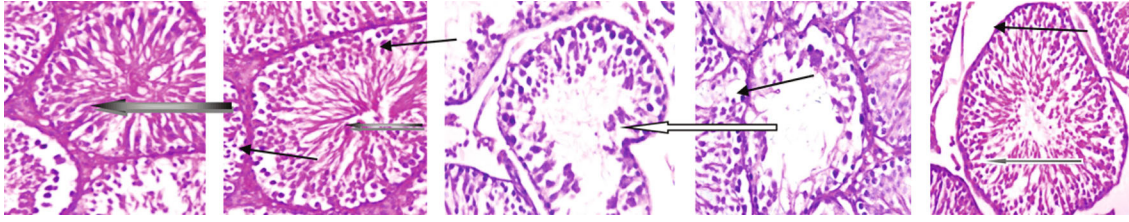


FIGURE 8: Photomicrographs of testis sections stained by hematoxylin and eosin after administration of Proxeed Plus to rats after 7 days: (a) control group showing normal testicular architecture. Normal germ cell layer (spanned) and normal maturation stages, there are normal spermatogonia cells (blue arrow) and normal Sertoli cells (red arrow), the lumen appears normal with presence of spermatozoa (white arrow). The interstitial spaces show normal Leydig cells (slender arrow). (b) Sham group showing normal testicular architecture. Normal maturation stages, normal spermatogonia cell (blue arrow) and normal Leydig and Sertoli cells (red arrow), the lumen appears normal with presence of spermatozoa (white arrow). The interstitial spaces show normal Leydig cells (slender arrow). (c) T/D group showing very poor architecture, generalized and severe degeneration of seminiferous tubules, fibrotic tubules and thickened propria, and sloughed germinal epithelial cells (slender arrow). (d) 1000 mg/kg Proxeed Plus after TD showing moderately normal testicular architecture, few seminiferous tubules with marked maturation arrest (black arrow). The interstitial spaces show normal Leydig cells (slender arrow). (e) 5000 mg/kg Proxeed Plus after TD showing normal testicular architecture, the lumen appears normal with presence of spermatozoa (white arrow). Normal Leydig and Sertoli cells (slender arrow) several normal seminiferous tubules with germ cells (slender arrow). Magnification  $\times 400$ .

TABLE 1: Effect of Proxeed Plus on sperm parameters of the reperfusion-induced testicular impaired rats.

Parameters	Control	Sham	T/D	T/D+PP 1000 mg/kg	T/D+PP 5000 mg/kg
<i>Four (4) hours of treatments</i>					
VAP	$17.92 \pm 1.20^{bc}$	$14.77 \pm 0.12^b$	$4.36 \pm 0.62^a$	$12.00 \pm 0.80^b$	$23.88 \pm 2.53^c$
VCL	$19.98 \pm 0.67^c$	$12.34 \pm 0.72^b$	$5.08 \pm 0.43^a$	$22.36 \pm 2.31^c$	$29.80 \pm 1.70^d$
VSL	$18.95 \pm 1.28^b$	$16.78 \pm 0.03^b$	$2.74 \pm 0.18^a$	$15.01 \pm 0.66^b$	$27.51 \pm 1.64^c$
Motility	$75.49 \pm 5.31^{bc}$	$63.99 \pm 2.87^b$	$39.58 \pm 4.50^a$	$82.86 \pm 2.31^c$	$90.54 \pm 1.15^d$
IM	$25.82 \pm 1.36^b$	$22.33 \pm 1.69^b$	$73.11 \pm 4.84^c$	$17.26 \pm 0.62^b$	$13.76 \pm 0.41^a$
STR	$68.30 \pm 0.35^{cd}$	$52.07 \pm 33.71^b$	$40.39 \pm 7.51^a$	$62.74 \pm 1.55^c$	$71.39 \pm 0.61^d$
LIN	$62.20 \pm 0.16^b$	$61.59 \pm 0.75^b$	$29.28 \pm 4.53^a$	$75.75 \pm 2.27^c$	$76.03 \pm 4.22^c$
PR	$49.57 \pm 6.09^c$	$31.98 \pm 1.25^b$	$18.10 \pm 1.09^a$	$43.92 \pm 2.65^c$	$50.95 \pm 0.89^c$
NP	$12.63 \pm 0.45^a$	$43.05 \pm 3.33^c$	$38.17 \pm 0.80^c$	$25.61 \pm 2.09^b$	$13.92 \pm 1.20^a$
WOB	$71.21 \pm 0.82^b$	$84.46 \pm 3.45^{bc}$	$83.18 \pm 0.85^{bc}$	$61.54 \pm 2.07^a$	$93.33 \pm 1.88^c$
MAD	$2.07 \pm 0.08^b$	$1.41 \pm 0.20^b$	$0.66 \pm 0.16^a$	$3.53 \pm 0.27^c$	$5.89 \pm 0.23^d$
ALH	$0.21 \pm 0.06^a$	$0.29 \pm 0.02^b$	$0.17 \pm 0.01^a$	$0.32 \pm 0.02^b$	$0.71 \pm 0.02^c$
BCF	$0.54 \pm 0.09^a$	$1.25 \pm 0.14^b$	$0.44 \pm 0.22^a$	$2.62 \pm 0.02^c$	$3.13 \pm 0.12^d$
<i>Seven (7) days of treatments</i>					
VAP ( $\mu\text{m/s}$ )	$18.51 \pm 1.07^b$	$16.62 \pm 3.07^b$	$3.52 \pm 0.28^a$	$19.39 \pm 0.28^b$	$26.54 \pm 4.41^c$
VCL ( $\mu\text{m/s}$ )	$27.03 \pm 3.90^c$	$26.66 \pm 1.24^c$	$2.61 \pm 0.56^a$	$16.22 \pm 1.94^b$	$29.01 \pm 0.41^c$
VSL ( $\mu\text{m/s}$ )	$24.04 \pm 0.53^c$	$22.17 \pm 2.10^c$	$1.16 \pm 0.09^a$	$11.33 \pm 1.88^b$	$33.09 \pm 4.49^d$
Motility	$85.49 \pm 1.81^b$	$78.58 \pm 0.52^b$	$22.52 \pm 1.12^a$	$87.99 \pm 3.30^b$	$97.06 \pm 2.10^c$
IM	$20.95 \pm 1.72^a$	$23.66 \pm 0.47^a$	$71.21 \pm 3.39^b$	$20.29 \pm 4.74^a$	$18.58 \pm 0.44^a$
STR	$82.57 \pm 5.21^c$	$74.37 \pm 2.58^c$	$21.57 \pm 1.27^a$	$59.35 \pm 4.08^b$	$92.76 \pm 4.02^d$
LIN	$81.32 \pm 6.17^b$	$77.81 \pm 3.99^b$	$22.55 \pm 1.60^a$	$73.61 \pm 2.66^b$	$83.48 \pm 3.44^b$
PR	$62.51 \pm 2.62^c$	$56.38 \pm 8.62^{bc}$	$10.38 \pm 0.39^a$	$48.84 \pm 10.61^b$	$58.27 \pm 10.66^{bc}$
NP	$31.74 \pm 4.42^c$	$46.55 \pm 2.35^d$	$43.98 \pm 9.03^d$	$23.94 \pm 3.73^b$	$9.74 \pm 0.36^a$
WOB	$80.66 \pm 9.84^b$	$64.06 \pm 3.27^a$	$62.62 \pm 4.07^a$	$58.06 \pm 1.23^a$	$48.58 \pm 5.40^a$
MAD	$5.80 \pm 0.52^b$	$5.72 \pm 0.50^b$	$0.25 \pm 0.04^a$	$4.28 \pm 0.86^b$	$10.29 \pm 0.04^c$
ALH ( $\mu\text{m}$ )	$1.57 \pm 0.35^b$	$2.39 \pm 0.05^c$	$0.14 \pm 0.03^a$	$1.19 \pm 0.20^b$	$3.08 \pm 1.58^d$
BCF (Hz)	$4.09 \pm 0.94^c$	$2.27 \pm 0.49^b$	$0.25 \pm 0.13^a$	$2.98 \pm 0.94^b$	$5.61 \pm 0.13^d$

VAP: average path velocity; VCL: curvilinear velocity; VSL: straight-line velocity; ALH: amplitude of lateral head; BCF: beat cross frequency; LIN: linearity; STR: straightness; WOB: wobble; MAD: mean move angle degree. Data are the mean  $\pm$  SD of triplicate determination. Values followed by different superscript alphabets are significantly different.



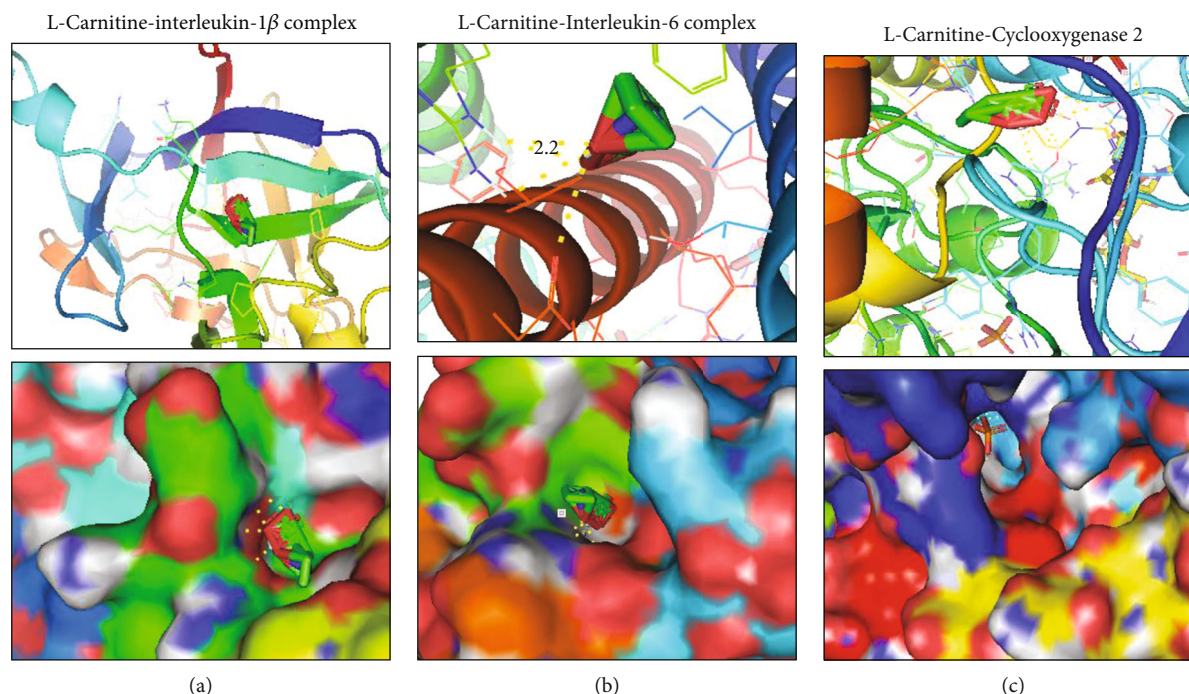


FIGURE 9: Receptor-ligand interaction of inflammatory markers with the Proxeed Plus backbone (L-carnitine): (a) L-carnitine-interleukin-1 $\beta$  complex; (b) L-carnitine-interleukin-6 complex; (c) L-carnitine-cyclooxygenase 2 complex. The upper panel shows the interacting amino acid residues and the binding distances, while the lower panels show the ligand interaction in the binding pocket of the receptors.

TABLE 2: Docking profile of inflammatory and antioxidant markers with the Proxeed Plus scaffold (L-carnitine).

Protein targets	Binding affinity (kcal/mol)	Binding distance (Å)	Interacting atom (protein-ligand)	Interacting amino acid
Interleukin-1 $\beta$	-5.5	4.9	H-O	GLU 64
Interleukin-6	-5.9	2.2	H-O	ARG 104
Cyclooxygenase 2	-6.8	3.1	H-N	ASN 144

in this study,  $H_2O_2$  and MDA were assessed as indicators of oxidative damage of cellular macromolecules. Consistent with our expectation, T/D considerably raised the testicular levels of  $H_2O_2$  and MDA but depleted protein levels.

The observed decrease in the total protein in T/D could be attributed to the decreased levels of the antioxidant enzymes which are known to constitute the total protein pool. Such a decrease in total protein could be detrimental to cellular homeostasis [68]. This will negatively affect the metabolic activities within the testis and consequently the health of the organ. MDA is a product of lipid peroxidation and a marker of oxidative stress that impairs physiological mechanisms in the human body because of its ability to react with macromolecules such as proteins and DNA [69]. Herein, the testicular-protective potential of PP could be highly linked to its strong antioxidant characteristics as revealed by decreased levels of  $H_2O_2$  and MDA in the treated rats. Similarly, PP induced significant enrichment of the antioxidant capability of the testis as evidenced by dose-dependent elevation of the testicular levels of free radical scavengers including the catalase (CAT), glutathione reductase (GSH), glutathione S-transferase (GST), superoxide dismutase (SOD), and glutathione peroxidase (GPx) relative to

the T/D groups thus protecting against ischemia-reperfusion-induced oxidative stress during I/R of rats' testes.

It is well established that PP has a great pool of nutrients with high antioxidant activities like zinc, L-carnitine, acetyl-L-carnitine, fumarate, CoQ10, folic acid, fructose, vitamin C, and vitamin B12 [35]. Accordingly, the antioxidant activities of PP could be attributed to the synergetic effect of its highly rich antioxidant components; zinc is well known to increase the levels of glutathione and antioxidant enzyme activities [38]. Vitamin E scavenges lipid peroxide radicals and limits the peroxidation of polyunsaturated fatty acids in the spermatozoa membrane [24]. L-carnitine and L-acetyl carnitine control the flow of the acetyl group via the cell membrane thus reducing the levels of toxic intracellular acetyl-CoA to protect spermatozoa from oxidative stress and support sperm maturation and male reproductive health [37].

Our results are consistent with previous studies which reported that L-carnitine has antioxidant activities and enhances the reproductive health and functions. In fact, clinical studies have indicated that oral administration of L-carnitine improves sperm quality of patients with idiopathic asthenozoospermia [30] and has also been used for the

treatment of idiopathic and varicocele-associated oligoasthenospermia [31]. In addition, Lenzi et al. [32] successfully used L-carnitine in idiopathic infertile males while another study demonstrated that a combination of L-carnitine+acetyl-L-carnitine increased sperm count in patients with echographic features of genital inflammation [33].

Consistent with the testicular biochemical parameters, histopathological examination of testis of T/D rats presents evidence of testis abnormalities as indicated by a very poor architecture of the testis with several degenerated seminiferous tubules and degenerated germinal epithelial cells. These findings were in accordance with the study of Jahromi et al. [69] which reported that after torsion and 4h detorsion, degenerated germinal epithelial cells were present in the lumen of the seminiferous tubule in the T/D group. Treatment with the PP, particularly for 7 days, significantly reduced the aforementioned histotesticular abnormalities in a dose-dependent manner, suggesting the testicular-protective effect of the used supplement against ischemic/reperfusion injury.

Previous clinical studies have indicated that treatment with Proxeed Plus significantly increases the progressive sperm motility and total sperm count of oligoasthenozoospermia men compared to the placebo [39]. Another clinical trial with 175 idiopathic oligoasthenozoospermia men who could not impregnate their partners revealed that Proxeed Plus significantly improved the sperm volume and progressive motility compared to baseline [40]. In line with these studies, our study showed that treatment with Proxeed Plus has a protective effect on T/D-induced testicular damage. This is attributed to its ability to modulate anti-inflammatory response and improve the antioxidant system, thus decreasing the levels of free radicals within the testis and prevent oxidative stress-induced damages. This study therefore calls for further preclinical and clinical studies in patients with testicular or reproductive deficiencies.

## 5. Conclusion

Our results indicated that both short-term and long-term testicular T/D induce an inflammatory response, oxidative stress, and histoarchitectural alteration. Interestingly, conclusively, our study showed that treatment with Proxeed Plus has both short-term and long-term protective effects on T/D-induced testicular damage. This is attributed to its ability to modulate anti-inflammatory response and improve the antioxidant system, thus decreasing the levels of free radicals within the testis and preventing oxidative stress-induced damages.

## Data Availability

The datasets generated and/or analyzed in this study are available on reasonable request.

## Conflicts of Interest

The authors declare that they have no competing interests.

## Acknowledgments

All authors acknowledged the laboratory where the work was done. This work was supported by the Taif University Researchers Supporting Program (project number: TURSP-2020/269), Taif University, Saudi Arabia.

## References

- [1] G. Vaos and N. Zavras, "Antioxidants in experimental ischemia-reperfusion injury of the testis: where are we heading towards?," *World journal of methodology*, vol. 7, no. 2, pp. 37–45, 2017.
- [2] Y. Kumtepe, F. Odabasoglu, M. Karaca et al., "Protective effects of telmisartan on ischemia/reperfusion injury of rat ovary: biochemical and histopathologic evaluation," *Fertility and Sterility*, vol. 93, no. 4, pp. 1299–1307, 2010.
- [3] N. Luhtala, A. Aslanian, J. R. Yates 3rd, and T. Hunter, "Secreted Glioblastoma Nanovesicles Contain Intracellular Signaling Proteins and Active Ras Incorporated in a Farnesylation-dependent Manner," *The Journal of Biological Chemistry*, vol. 292, no. 2, pp. 611–628, 2017.
- [4] A. Ünsal, E. Devrim, C. Guven et al., "Propofol attenuates reperfusion injury after testicular torsion and detorsion," *World Journal of Urology*, vol. 22, no. 6, pp. 461–465, 2004.
- [5] E. N. Ringdahl and L. Teague, "Testicular torsion," *American Family Physician*, vol. 74, no. 10, pp. 1739–1743, 2006.
- [6] D. S. Sheriff, F. A. Elshaari, R. I. Elfagih, and I. Barassi, "Oxidative and antioxidative defense system in testicular torsion/detorsion," *Indian Journal of Urology*, vol. 27, no. 4, article 91436, pp. 479–484, 2011.
- [7] H. Akbas, M. Ozden, M. Kanko et al., "Protective antioxidant effects of carvedilol in a rat model of ischaemia-reperfusion injury," *Journal of International Medical Research*, vol. 33, no. 5, pp. 528–536, 2005.
- [8] D. W. Filho, M. A. Torres, A. L. Bordin, T. B. Crezcynski-Pasa, and A. Boveris, "Spermatic cord torsion, reactive oxygen and nitrogen species and ischemia-reperfusion injury," *Molecular Aspects of Medicine*, vol. 25, no. 1-2, pp. 199–210, 2004.
- [9] D. N. Granger and P. R. Kvietys, "Reperfusion injury and reactive oxygen species: the evolution of a concept," *Redox Biology*, vol. 6, pp. 524–551, 2015.
- [10] M. Shokoohi, A. Khaki, H. Shoorei, A. Khaki, M. Moghimian, and S. H. Abtahi-Eivary, "Hesperidin attenuated apoptotic-related genes in testicle of a male rat model of varicocele," *Andrology*, vol. 8, no. 1, pp. 249–258, 2020.
- [11] M. Moghimian, S.-H. Abtahi-Evari, M. Shokoohi, M. Amiri, and M. Soltani, "Effect of Syzygium aromaticum (clove) extract on seminiferous tubules and oxidative stress after testicular torsion in adult rats," *Physiology and Pharmacology*, vol. 21, pp. 343–350, 2018.
- [12] S. Arena, R. Iacona, P. Antonuccio et al., "Medical perspective in testicular ischemia-reperfusion injury," *Experimental and Therapeutic Medicine*, vol. 13, no. 5, pp. 2115–2122, 2017.
- [13] M. Al-Maghrebi and W. M. Renno, "The tACE/Angiotensin (1-7)/Mas Axis Protects Against Testicular Ischemia Reperfusion Injury," *Urology*, vol. 94, pp. 312.e1–312.e8, 2016.
- [14] J. MacMicking, Q. W. Xie, and C. Nathan, "Nitric oxide and macrophage function," *Annual Review of Immunology*, vol. 15, no. 1, pp. 323–350, 1997.

- [15] C. Welbourn, G. Goldman, I. Paterson, C. Valeri, D. Shepro, and H. Hechtman, "Pathophysiology of ischaemia reperfusion injury: central role of the neutrophil," *British Journal of Surgery*, vol. 78, no. 6, pp. 651–655, 1991.
- [16] G. Kadirvel, S. Kumar, and A. Kumaresan, "Lipid peroxidation, mitochondrial membrane potential and DNA integrity of spermatozoa in relation to intracellular reactive oxygen species in liquid and frozen-thawed buffalo semen," *Animal Reproduction Science*, vol. 114, no. 1-3, pp. 125–134, 2009.
- [17] S. I. Peris, J. F. Bilodeau, M. Dufour, and J. L. Bailey, "Impact of cryopreservation and reactive oxygen species on DNA integrity, lipid peroxidation, and functional parameters in ram sperm," *Molecular Reproduction and Development*, vol. 74, no. 7, pp. 878–892, 2007.
- [18] E. O. Kehinde, O. A. Mojiminiyi, A. H. Mahmoud, K. H. A. L. E. E. L. A. Al-Awadi, A. D. E. L. al-Hunayan, and A. E. Omu, "The significance of measuring the time course of serum malondialdehyde concentration in patients with torsion of the testis," *Journal of Urology*, vol. 169, no. 6, pp. 2177–2180, 2003.
- [19] N. Hosseini Ahar, A. Khaki, G. Akbari, and M. Ghafarinovin, "The effect of busulfan on body weight, testis weight and MDA enzymes in male rats," *International Journal of Women's Health and Reproduction Sciences*, vol. 2, no. 5, pp. 316–319, 2014.
- [20] E. Yuluğ, S. Türedi, E. Karagüzel, Ö. Kutlu, A. Menteşe, and A. Alver, "The short term effects of resveratrol on ischemia-reperfusion injury in rat testis," *Journal of Pediatric Surgery*, vol. 49, no. 3, pp. 484–489, 2014.
- [21] R. Korhonen, A. Lahti, H. Kankaanranta, and E. Moilanen, "Nitric oxide production and signaling in inflammation," *Current Drug Target-Inflammation & Allergy*, vol. 4, no. 4, pp. 471–479, 2005.
- [22] Y. M. Ha, S. W. Chung, J. M. Kim et al., "Molecular activation of NF- $\kappa$ B, pro-inflammatory mediators, and signal pathways in  $\gamma$ -irradiated mice," *Biotechnology Letters*, vol. 32, no. 3, pp. 373–378, 2010.
- [23] D. Sanocka and M. Kurpisz, "Reactive oxygen species and sperm cells," *Reproductive Biology and Endocrinology*, vol. 2, no. 1, pp. 12–17, 2004.
- [24] J. H. Jung and J. T. Seo, "Empirical medical therapy in idiopathic male infertility: promise or panacea?," *Clinical and Experimental Reproductive Medicine*, vol. 41, no. 3, pp. 108–114, 2014.
- [25] J. Bremer, "Carnitine—metabolism and functions," *Physiological Reviews*, vol. 63, no. 4, pp. 1420–1480, 1983.
- [26] C. Jeulin, J. L. Dacheux, and J. C. Soufir, "Uptake and release of free L-carnitine by boar epididymal spermatozoa in vitro and subsequent acetylation rate," *Reproduction*, vol. 100, no. 1, pp. 263–271, 1994.
- [27] A. Enomoto, M. F. Wempe, H. Tsuchida et al., "Molecular identification of a novel carnitine transporter specific to human testis. Insights into the mechanism of carnitine recognition," *Journal of Biological Chemistry*, vol. 277, no. 39, pp. 36262–36271, 2002.
- [28] L. Johansen and T. Bøhmer, "Carnitine-binding related suppressed oxygen uptake by spermatozoa," *Archives of Andrology*, vol. 1, no. 4, pp. 321–324, 1978.
- [29] C. Jeulin and L. M. Lewin, "Role of free L-carnitine and acetyl-L-carnitine in post-gonadal maturation of mammalian spermatozoa," *Human Reproduction Update*, vol. 2, no. 2, pp. 87–102, 1996.
- [30] M. Costa, D. Canale, M. Filicori, S. D'Iddio, A. Lenzi, and Italian study group on carnitine and male infertility, "L-carnitine in idiopathic asthenozoospermia: a multicenter study," *Andrologia*, vol. 26, no. 3, pp. 155–159, 1994.
- [31] G. Cavallini, A. P. Ferraretti, L. Gianaroli, G. Biagiotti, and G. Vitali, "Cinnoxamicam and L-carnitine/acetyl-L-carnitine treatment for idiopathic and varicocele-associated oligoasthenospermia," *Journal of Andrology*, vol. 25, no. 5, pp. 761–770, 2004.
- [32] A. Lenzi, F. Lombardo, P. Sgrò et al., "Use of carnitine therapy in selected cases of male factor infertility: a double-blind crossover trial," *Fertility and Sterility*, vol. 79, no. 2, pp. 292–300, 2003.
- [33] E. Vicari and A. E. Calogero, "Effects of treatment with carnitines in infertile patients with prostatovesiculourethritis," *Human Reproduction*, vol. 16, no. 11, pp. 2338–2342, 2001.
- [34] S. M. Fenkci, V. Fenkci, O. Oztekin, S. Rota, and N. Karagenc, "Serum total L-carnitine levels in non-obese women with polycystic ovary syndrome," *Human Reproduction*, vol. 23, no. 7, pp. 1602–1606, 2008.
- [35] S. Micic, N. Lalic, N. Bojanic, D. Djordjevic, A. Virmani, and A. Agarwal, "Oligoasthenospermic men treated with Proxeed Plus showed correlation between sperm motility and seminal carnitine," *Fertility and Sterility*, vol. 106, no. 3, pp. e298–e299, 2016.
- [36] U. Schagdarsurengin and K. Steger, "Epigenetics in male reproduction: effect of paternal diet on sperm quality and offspring health," *Nature Reviews Urology*, vol. 13, no. 10, pp. 584–595, 2016.
- [37] X. Zhou, F. Liu, and S. Zhai, "Effect of L-carnitine and/or L-acetyl-carnitine in nutrition treatment for male infertility: a systematic review," *Asia Pacific Journal of Clinical Nutrition*, vol. 16, Supplement 1, pp. 383–390, 2007.
- [38] L. Y. Al-Ayadhi and N. E. Elamin, "Camel milk as a potential therapy as an antioxidant in autism spectrum disorder (ASD)," *Evidence-based Complementary and Alternative Medicine*, vol. 2013, 8 pages, 2013.
- [39] G. Busetto, A. Agarwal, A. Virmani et al., "Effect of metabolic and antioxidant supplementation on sperm parameters in oligoasthenoteratozoospermia, with and without varicocele: a double-blind placebo-controlled study," *Andrologia*, vol. 50, no. 3, article e12927, 2018.
- [40] S. Micic, N. Lalic, D. Djordjevic et al., "Double-blind, randomised, placebo-controlled trial on the effect of L-carnitine and L-acetylcarnitine on sperm parameters in men with idiopathic oligoasthenozoospermia," *Andrologia*, vol. 51, no. 6, article e13267, 2019.
- [41] M. S. Aydin, R. Kazancioglu, M. Seker et al., "Effects of Proxeed Plus in the prevention and treatment of cisplatin nephrotoxicity: an experimental rat study," in *55th Congress of the European-Renal-Association (ERA) and European-Dialysis-and-Transplantation-Association (EDTA)*, Copenhagen, Denmark, 2018.
- [42] F. Firat, F. Erdemir, E. Kölükçü, F. Gevrek, İ. Benli, and V. Ünsal, "Oxytocin in The Prevention of injury due to testicular torsion/detorsion in rats," *Ulusal Travma ve Acil Cerrahi Dergisi*, vol. 24, no. 2, pp. 89–96, 2018.
- [43] A. Gezici, H. Ozturk, H. Buyukbayram, H. Ozturk, and H. Okur, "Effects of gabexate mesilate on ischemia-reperfusion-induced testicular injury in rats," *Pediatric Surgery International*, vol. 22, no. 5, pp. 435–441, 2006.



- [44] J. O. Sangodele, Z. Inuwa, B. Lawal, G. Adebayo-Gege, B. J. Okoli, and F. Mtunzi, "Proxead plus salvage rat testis from ischemia-reperfusion injury by enhancing antioxidant's activities and inhibition of iNOS expression," *Biomedicine & Pharmacotherapy*, vol. 133, article 111086, 2021.
- [45] B. Lawal, O. K. Shittu, F. I. Oibiokpa, H. Mohammed, S. I. Umar, and G. M. Haruna, "Antimicrobial evaluation, acute and sub-acute toxicity studies of *Allium sativum*," *Journal of Acute Disease*, vol. 5, no. 4, pp. 296–301, 2016.
- [46] R. Varshney and R. Kale, "Effects of calmodulin antagonists on radiation-induced lipid peroxidation in microsomes," *International Journal of Radiation Biology*, vol. 58, no. 5, pp. 733–743, 1990.
- [47] A. G. Gornall, C. J. Bardawill, and M. M. David, "Determination of serum proteins by means of the biuret reaction," *Journal of Biological Chemistry*, vol. 177, no. 2, pp. 751–766, 1949.
- [48] M. Koroliuk, L. Ivanova, I. Mañorova, and V. Tokarev, "A method of determining catalase activity," *Laboratornoe Delo*, vol. 1, pp. 16–19, 1988.
- [49] A. K. Sinha, "Colorimetric assay of catalase," *Analytical Biochemistry*, vol. 47, no. 2, pp. 389–394, 1972.
- [50] H. P. Misra and I. Fridovich, "The role of superoxide anion in the autoxidation of epinephrine and a simple assay for superoxide dismutase," *Journal of Biological Chemistry*, vol. 247, no. 10, pp. 3170–3175, 1972.
- [51] I. K. Smith, T. L. Vierheller, and C. A. Thorne, "Assay of glutathione reductase in crude tissue homogenates using 5,5'-dithiobis(2-nitrobenzoic acid)," *Analytical Biochemistry*, vol. 175, no. 2, pp. 408–413, 1988.
- [52] M. Hu and C. Dillard, "[41] Measurement of protein thiol groups and glutathione in plasma," *Methods in Enzymology*, vol. 233, no. 3, pp. 380–385, 1994.
- [53] R. H. Jaskot, E. G. Charlet, E. C. Grose, M. A. Grady, and J. H. Roycroft, "An automated analysis of glutathione peroxidase, S-transferase, and reductase activity in animal tissue," *Journal of Analytical Toxicology*, vol. 7, no. 2, pp. 86–88, 1983.
- [54] W. H. Habig, M. J. Pabst, and W. B. Jakoby, "Glutathione S-transferases: the first enzymatic step in mercapturic acid formation," *Journal of Biological Chemistry*, vol. 249, no. 22, pp. 7130–7139, 1974.
- [55] J. O. Olugbodi, O. David, E. N. Oketa, B. Lawal, B. J. Okoli, and F. Mtunzi, "Silver nanoparticles stimulates spermatogenesis impairments and hematological alterations in testis and epididymis of male rats," *Molecules*, vol. 25, no. 5, p. 1063, 2020.
- [56] U. Igwebuike and U. U. Eze, "Morphological characteristics of the small intestine of the African pied crow (*Corvus albus*)," *Animal Research International*, vol. 7, pp. 1116–1120, 2010.
- [57] B. Lawal, Y.-L. Liu, N. Mokgautsi et al., "Pharmacoinformatics and preclinical studies of NSC765690 and NSC765599, potential STAT3/CDK2/4/6 inhibitors with antitumor activities against NCI60 human tumor cell lines," *Biomedicine*, vol. 9, no. 1, p. 92, 2021.
- [58] J.-C. Lee, A. T. H. Wu, J.-H. Chen et al., "HNC0014, a multi-targeted small-molecule, inhibits head and neck squamous cell carcinoma by suppressing c-met/STAT3/CD44/PD-L1 oncoimmune signature and eliciting antitumor immune responses," *Cancers (Basel)*, vol. 12, no. 12, p. 3759, 2020.
- [59] B. Lawal, C.-Y. Lee, N. Mokgautsi et al., "mTOR/EGFR/iNOS/MAP2K1/FGFR/TGFB1 are druggable candidates for N-(2,4-difluorophenyl)-2',4'-difluoro-4-hydroxybiphenyl-3-carboxamide (NSC765598), with consequent anticancer implications," *Frontiers in Oncology*, vol. 11, 2021.
- [60] L. Bosca, M. Zeini, P. Traves, and S. Hortelano, "Nitric oxide and cell viability in inflammatory cells: a role for NO in macrophage function and fate," *Toxicology*, vol. 208, no. 2, pp. 249–258, 2005.
- [61] M. A. Cassatella, L. Meda, S. Bonora, M. Ceska, and G. Constantin, "Interleukin 10 (IL-10) inhibits the release of proinflammatory cytokines from human polymorphonuclear leukocytes. Evidence for an autocrine role of tumor necrosis factor and IL-1 beta in mediating the production of IL-8 triggered by lipopolysaccharide," *The Journal of Experimental Medicine*, vol. 178, no. 6, pp. 2207–2211, 1993.
- [62] H. Ozturk, H. Ozturk, E. H. Terzi, G. Bugdayci, and A. Duran, "Interleukin 10 reduces testicular damage in experimental testicular ischemia/reperfusion injury," *Urology*, vol. 83, no. 2, pp. 508.e1–508.e6, 2014.
- [63] A. A. Beharka, D. Wu, M. Serafini, and S. N. Meydani, "Mechanism of vitamin E inhibition of cyclooxygenase activity in macrophages from old mice: role of peroxynitrite," *Free Radical Biology and Medicine*, vol. 32, no. 6, pp. 503–511, 2002.
- [64] Q. Jiang, I. Elson-Schwab, C. Courtemanche, and B. N. Ames, "gamma-Tocopherol and its major metabolite, in contrast to alpha-tocopherol, inhibit cyclooxygenase activity in macrophages and epithelial cells," *Proceedings of the National Academy of Sciences*, vol. 97, no. 21, pp. 11494–11499, 2000.
- [65] A. Topal, G. Alak, M. Ozkaraca et al., "Neurotoxic responses in brain tissues of rainbow trout exposed to imidacloprid pesticide: assessment of 8-hydroxy-2-deoxyguanosine activity, oxidative stress and acetylcholinesterase activity," *Chemosphere*, vol. 175, pp. 186–191, 2017.
- [66] B. Lawal, O. K. Shittu, F. I. Oibiokpa, E. B. Berinyuy, and H. Mohammed, "African natural products with potential antioxidants and hepatoprotective properties: a review," *Clinical Phytoscience*, vol. 2, no. 1, pp. 1–66, 2017.
- [67] J. Ibrahim, A. Y. Kabiru, T. Abdulrasheed-Adeleke, B. Lawal, and A. H. Adewuyi, "Antioxidant and hepatoprotective potentials of curcuminoid isolates from turmeric (*Curcuma longa*) rhizome on CCl4-induced hepatic damage in Wistar rats," *Journal of Taibah University for Science*, vol. 14, no. 1, pp. 908–915, 2020.
- [68] O. K. Shittu, B. Lawal, B. U. Alozieuwa, G. M. Haruna, A. N. Abubakar, and E. B. Berinyuy, "Alteration in biochemical indices following chronic administration of methanolic extract of Nigeria bee propolis in Wistar rats," *Asian Pacific Journal of Tropical Disease*, vol. 5, no. 8, pp. 654–657, 2015.
- [69] A. R. Jahromi, R. Rasooli, Y. Kamali, N. Ahmadi, and E. Sattari, "Short-term effects of date palm extract (*Phoenix dactylifera*) on ischemia/reperfusion injury induced by testicular torsion/detorsion in rats," *Pharmacognosy research*, vol. 9, no. 1, pp. 69–73, 2017.