



EFFECT OF ETHANOL LEAF EXTRACT OF *Cassia angustifolia* EXTRACT ON HEART AND LIPID PROFILE OF WISTER RATS

WAZIS CHAMA HARUNA¹, JOSEPH OYEPATA SIMEON^{2, *}, MODUPE BUILDERS², JOSEPH OPEYEMI TOSIN³

1. Department of Pharmacology and Toxicology, Faculty of Pharmacy, University of Maiduguri, Borno State, Nigeria.
2. Department of Pharmacology, Faculty of Pharmacy, Bingham University, Nasarawa, Nigeria.
3. Department of Pharmacology, Faculty of Basic Medical Sciences, University of Port Harcourt, Rivers State, Nigeria.

ABSTRACT

The human heart is an organ that pumps blood throughout the body via the circulatory system, supplying oxygen and nutrients to the tissues and removing carbon dioxide and other wastes. Damage to tissue or cells of the heart can be very fatal. *Cassia angustifolia* is a plant regularly consumed by the locals to treat gastrointestinal issues. The aim of this study is to determine the effect of *Cassia angustifolia* on the heart and other cardiovascular parameter. Animals of either sex were selected. Group 1 received distilled water (10 ml/kg), while group 2, 3 and 4 received *Cassia angustifolia* 50, 100 and 200 mg/kg respectively. Animals were kept in standard cages and given access to the extract, water and food orally for 28 days, after which they were weighed and sacrificed. Blood was collected by cardiac puncture and taken immediately for hematological and chemo pathological analysis. The histological toxic potential of the plant on the kidney was studied using haematotoxilin and eosin (H&E) staining technique. There was significant ($P<0.05$) decrease in RBC, HGB, MCV, while there was no change in the level of neutrophiles, basophiles, eosinophiles and platelets. The extract did not cause significant ($P<0.05$) change in the level of cholesterol, low density lipoprotein (LDL) and triglyceride. There was significant ($P<0.05$) increase in the level of high-density lipoprotein (HDL). Histological observation revealed slight to no damage to tissue of the heart. Result obtained suggests that the plant maybe of cardiovascular significance, particularly when taken for a prolong period of time.

KEYWORDS: *Cassia angustifolia*, heart, rat, cholesterol.

INTRODUCTION

In humans, the heart is roughly the size of a large fist and weighs between about 10 to 12 ounces (280 to 340 grams) in men and 8 to 10 ounces (230 to 280 grams) in women [1]. The physiology of the heart basically comes down to "structure, electricity and plumbing. The human heart has four chambers: two upper chambers (the atria) and two lower ones (the ventricles), according to the National Institute of Health [2]. The right atrium and right ventricle together make up the right heart, and the left atrium and left ventricle make up the left heart. A wall of muscle called the septum separates the two sides

of the heart [3]. A double-walled sac called the pericardium encases the heart, which serves to protect the heart and anchor it inside the chest. Between the outer layer, the parietal pericardium, and the inner layer, the serous pericardium, runs pericardial fluid, which lubricates the heart during contractions and movements of the lungs and diaphragm [4].

The heart's outer wall consists of three layers. The outermost wall layer, or epicardium, is the inner wall of the pericardium. The middle layer, or myocardium, contains the muscle that contracts [5]. The inner layer, or endocardium, is the lining that

*Corresponding author: simeon4unme@yahoo.com; +2348038248352

ajopred.com

contacts the blood. The tricuspid valve and the mitral valve make up the atrioventricular (AV) valves, which connect the atria and the ventricles. The pulmonary semi-lunar valve separates the right ventricle from the pulmonary artery, and the aortic valve separates the left ventricle from the aorta. The heartstrings, or chordae tendinae, anchor the valves to heart muscles. The sinoatrial node produces the electrical pulses that drive heart contractions [6].

Cardiovascular disease generally refers to conditions that involve narrowed or blocked blood vessels that can lead to a heart attack, chest pain (angina) or stroke. Other heart conditions, such as those that affect your heart's muscle, valves or rhythm, also are considered forms of heart disease [7]. Many forms of heart disease can be prevented or treated with healthy lifestyle choices. Traditionally, herbs have been consumed for various reasons. Most of these plants have unsuspected and unintended effect that maybe serendipitous or deleterious consequences [8].

Cassia angustifolia is a shrubby plant that reaches 0.5–1, rarely two, metres in height with a branched, pale-green erect stem and long spreading branches bearing four or five pairs of leaves. These leaves form complex, feathery, mutual pairs. The leaflets vary from 4 to 6 pairs, fully edged, with a sharp top [9]. The midribs are equally divided at the base of the leaflets. The flowers are in raceme interior blossoms, big in size, coloured yellow that tends to brown. Its legume fruit are horned, broadly oblong, compressed and flat and contain about six seeds. When cultivated, the plants are cut down semi-annually, dried in the sun, stripped and packed in palm-leaf bags. It also serves as a fungicide [10]. Modern medicine has used extracts since at least the 1950s as a laxative. If accidentally ingested by infants, it can cause side effects such as severe diaper rash [11]. The active ingredients have several glycosides which interact with immune cells in the colon. The aim of this study is to investigate the effect of ethanol extract of *Cassia angustifolia* on the heart and lipid profile of rats.

MATERIALS AND METHODS

Animals

Male and female wister rats were obtained from Bingham University, Animal House. They were maintained on standard animal pellets and given water *ad libitum*. Permission and approval for animal studies were obtained from the College of Health Sciences Animal Ethics Committee of Bingham University.

Plant collection

Leaves of *Cassia angustifolia* were collected from its natural habitat from nearby Karu village, Nasarawa State, Nigeria. The plant was authenticated from Department of Botany, Bingham University, Nasarawa State Nigeria.

Plant extraction

The leaves were shadow dried for two weeks. The dried plant material was further reduced into small pieces and pulverized. The powdered material was macerated in 70% ethanol. The liquid filtrates were concentrated and evaporated to dryness at 40°C *in vacuum* using rotary evaporator. The ethanol extract was stored at -4°C until used.

Animal study

Twenty-four (24) rats of either sex (159-283g) were selected and randomized into four groups of six rats per group. Group 1 served as the control and received normal saline (10ml/kg) while the rats in groups 2, 3 and 4 were giving 50, 100, and 200 mg/kg of extract respectively. The weights of the rats were recorded at the beginning of the experiment and at weekly intervals. The first day of dosing was taken as D0 while the day of sacrifice was designated as D29.

Haematological analysis

The rats were sacrificed on the 29th day of experiment. Blood samples were collected via cardiac puncture. One portion of the blood was collected into sample bottles containing EDTA for hematological analysis such as Hemoglobin concentration, white blood cell counts (WBC), differentials (neutrophils, eosinophils, basophils, lymphocyte and monocyte), red blood cell count (RBC), platelets and hemoglobin (Hb) concentration using automated Haematology machine (Cell-Dyn, Abbott, USA).

Chempathology analysis

Second portion of the blood was collected into plain bottle, allowed to clot and centrifuged at 300rpm for 10 minutes. The serum collected was used to estimate biochemical parameters such as cholesterol, triglyceride, high density lipopolysaccharide (HDL) and low-density lipopolysaccharide (LDL).

Histological study

The heart of the animals were surgically removed and weighed and a part of each was fixed in 10% formaldehyde for histological processes.

Statistical analysis

Data were expressed as the Mean \pm Standard Error of the Mean (SEM). Data were analyzed statistically using one-way Analysis of Variance (ANOVA) followed by Dunnett's post hoc test for multiple comparisons between the control and treated groups. Values of $P \leq 0.05$ were considered significant.

RESULTS

Effect of 28 days oral administration of *Cassia angustifolia* on hematological parameters in rats

Cassia angustifolia caused significant ($p < 0.05$) decrease in the level of red blood cell, hemoglobin, platelet etc. and significantly ($p < 0.05$) caused an increase in mean corpuscular hemoglobin concentration in the rats at the dose level of 50 mg/kg compared to the control. The level of basophiles, neutrophils, eosinophils and lymphocytes were however not significantly ($p < 0.05$) affected by mean corpuscular hemoglobin concentration (Table 1).

Effect of 28 days oral administration of ethanol extract of *Cassia angustifolia* on relative organ to body weight ratio in rats.

The heart was observed to be slightly increased in rats with dose level of 100 mg/kg of the extract (Table 2).

Effect of 28 days oral administration of ethanol extract of *Cassia angustifolia* on lipid profile in Wistar rats

Significant ($p < 0.05$) increases were observed in total cholesterol and HDL levels at 100 mg/kg dose level of *Cassia angustifolia* when compared to the control. The extract did not produce significant changes in all other parameters (LDL, TRIG levels) studied when compared to the control (Table 3)

Effect of 28 days oral administration of ethanol extract of *Cassia angustifolia* on Histology of Heart in rats

Histopathological examination of heart showed slight necrosis of cardiac muscles at all doses and normal features at control (10 ml/kg). Study reveals normal elongated and rod-shaped cells, striated muscles and blood vessels (Figure 1).

DISCUSSION

Without the heart the blood would not be pumped through our blood vessels. But this is what is

needed for oxygen/carbon dioxide exchange in tissues and lungs [12]. It is also needed for all the nutrients to reach all cells. It is further needed to transport the immune cells into every corner of the body where they are required. And of course our hormones are carried in the blood stream, pumped by the heart and they have effects wherever matching hormone receptors are located in the body [12]. Study was not done on the functionality and performance of the heart with regards to blood pressure and pulse rate [13].

In this study the effect of the plant on the heart and vascular parameters were examined. Ethanol extract of leaves of *C. angustifolia* resulted in significant ($*p < 0.05$) decrease in the red blood cell, hemoglobin and platelet when compared to the control group of rats. This indicated that the plant may either suppress the production of red blood cells, decrease the lifespan of red blood cells or causes problems with how the body uses iron. Anemia is a condition that develops when the blood lacks enough healthy red blood cells or hemoglobin [14]. Hemoglobin is a main part of red blood cells and binds oxygen. If the level of RBC too few or there is abnormal red blood cells, or hemoglobin is abnormal or low, the cells in the body will not get enough oxygen [15]. Also, the level of basophiles, neutrophils, eosinophils and lymphocytes were not affected by the extract. This indicates that the plant may not affect the body immune. It could also suggest that the plant may have immunomodulatory property. In this work, the effect of *Cassia angustifolia* on the lipid profile of rat. The level of most of the parameters such as low density lipoprotein (LDL), triglyceride and cholesterol were unchanged when compared to the group that received normal saline. There was significant increase in the level of high density lipoprotein (HDL). Clinically and nutritionally, LDL cholesterol is usually considered bad cholesterol, because it contributes to fatty deposition in arteries, a condition known as atherosclerosis [16]. This condition clogs the arteries, raises the value of peripheral resistance and increases the risk for cardiovascular diseases, such as heart attack, stroke and peripheral artery disease. HDL acts as a scavenger, removing LDL (bad) cholesterol away from arteries and back to the liver, where it is broken down and passed from the body [17]. But HDL cholesterol does not completely remove LDL cholesterol from the blood vessels. Only one-third to one-fourth of blood cholesterol is carried by HDL [17]. Triglyceride stores excess energy.

Table 1: Effect of 28 days oral administration of ethanol leaf extract of *Cassia angustifolia* on hematological parameters in wistar rats.

Hematological parameters	Treatment (mg/kg)			
	DW(1ml/kg)	50 mg/kg	100 mg/kg	200 mg/kg
WBC ($\times 10^9/L$)	7.67 \pm 0.772	7.74 \pm 1.419	3.700 \pm 0.657*	6.420 \pm 1.085
RBC ($\times 10^{12}/L$)	8.21 \pm 0.37	8.65 \pm 0.20	6.11 \pm 0.35*	7.91 \pm 0.27
HGB (g/dL)	14.92 \pm 0.66	14.24 \pm 0.46	10.93 \pm 0.76*	13.58 \pm 0.77
HCT (g/dL)	54.27 \pm 2.13	55.60 \pm 2.75	34.67 \pm 2.28*	52.41 \pm 2.73
MCV (fL)	66.62 \pm 0.93	65.40 \pm 1.44	57.17 \pm 0.31*	69.60 \pm 1.72
MCH (pg)	19.17 \pm 0.17	17.80 \pm 1.02	18.83 \pm 0.37	18.80 \pm 0.20
MCHC (g/dL)	34.17 \pm 0.16	32.30 \pm 0.72	35.50 \pm 0.53*	30.62 \pm 0.74
PLT ($\times 10^9/L$)	626.86 \pm 46.71	577.20 \pm 93.32	242.13 \pm 45.28*	688.40 \pm 45.26
LYM (%)	76.45 \pm 5.16	74.00 \pm 5.19	75.83 \pm 6.33	75.40 \pm 5.23
NEUT ($\times 10^9/L$)	20.86 \pm 4.57	21.83 \pm 2.69	25.33 \pm 5.66	21.36 \pm 4.17
EOSI ($\times 10^9/L$)	2.55 \pm 0.24	3.44 \pm 0.65	2.87 \pm 0.36	2.32 \pm 0.51
BASO ($\times 10^9/L$)	2.12 \pm 0.19	2.60 \pm 0.85	2.44 \pm 1.77	3.45 \pm 1.64

Data presented as Mean \pm SEM: n = 6, One way ANOVA, followed by Dunnett's post hoc for multiple comparison *significantly different from the distilled water (DW) control at p<0.05. DW = distilled water

(WBC = white blood cells, RBC = red blood cells, HGB = hemoglobin, HCT = hematocrit, MCV = mean corpuscular volume, MCH = mean corpuscular hemoglobin, MCHC = mean corpuscular hemoglobin concentration, PLT = platelet, LYM = lymphocyte, NEUT = neutrophils, EOSI = eosinophils, BASO = basophils).

Table 2: effect of 28 days oral administration of ethanol extract of *Cassia angustifolia* on relative organ to body weight ratio in rats.

Treatment(mg/kg)	HEART
DW(10ml/kg)	0.47±0.07
c.a 50 mg/kg	0.40±0.03
c.a 100 mg/kg	0.65±0.12
c.a 200 mg/kg	0.49±0.02

Table 3: Effect of 28 days oral administration of *Cassia angustifolia* on serum lipid profile in rats.

Lipid profiles	Treatment (mg/kg)			
	DW(10ml/kg)	50	100	200
CHOL (mmol/L)	47.30±8.46	62.80±6.26*	48.40±2.75	45.75±9.42
HDL (mmol/L)	48.30±3.18	62.00±4.14*	47.20±1.9	54.71±3.95
LDL (mmol/L)	6.80±1.94	7.46±1.75	7.72±4.249	6.57±3.67
TRIG (mmol/L)	62.45±2.34	58.39±8.55	65.45±6.81	62.33±5.98

*Significantly different from the distilled water (DW) control at $p < 0.05$. (CHOL = total cholesterol, HDL = high density lipoprotein, LDL = low density lipoprotein, TRIG = triglycerides).

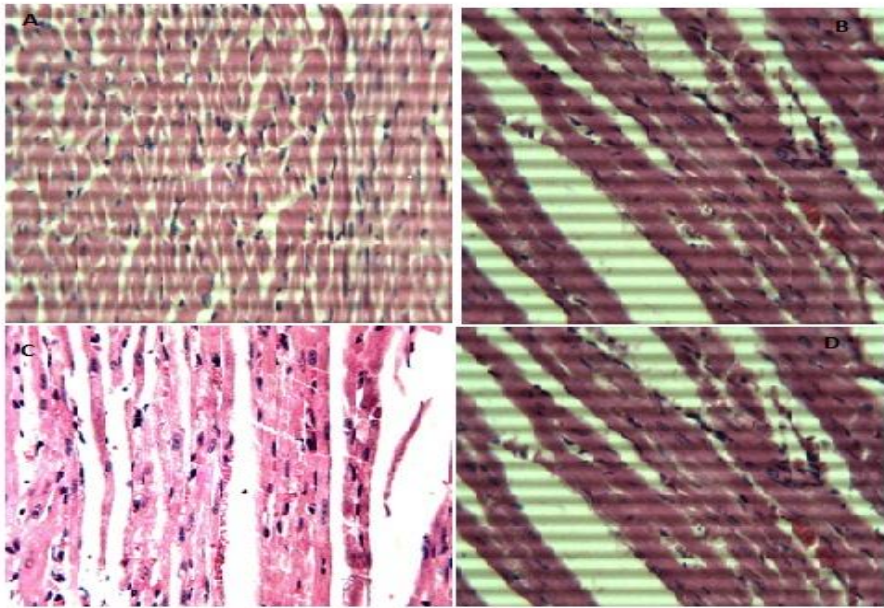


Figure 1: Photomicrograph of the heart (Hematoxylin and eosin. H and E $\times 100$). (A) Control group, Shows normal myocardium. (B) 50 mg/kg *Cassia angustifolia*, slight necrosis of myocardium (MN). (C) 100 mg/kg, slight necrosis of myocardium. (D) 200 mg/kg, slight necrosis of myocardium (MN).

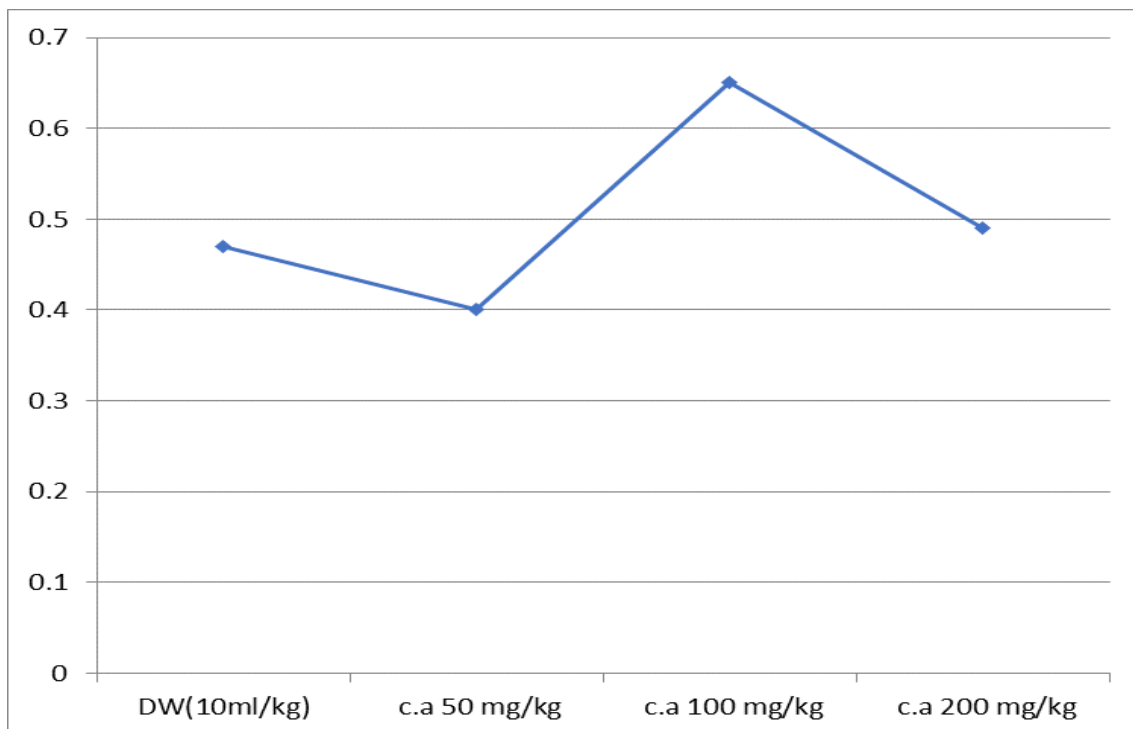


Figure 2: effect of 28 days oral administration of ethanol extract of *Cassia angustifolia* on relative organ to body weight ratio in rats.

High triglycerides may contribute to hardening of the arteries or thickening of the artery walls (arteriosclerosis) — which increases the risk of cardiovascular disease. Extremely high triglycerides can also cause acute inflammation of the pancreas (pancreatitis) a high triglyceride level combined with high LDL cholesterol or low HDL (good) cholesterol is linked with fatty buildups within the artery walls, which increases the risk of heart attack and stroke [17,18,19]. The crucial risk factor for CVD includes a high level of LDL or low level of HDL-cholesterol. The association between a low level of HDL-cholesterol and an increased risk of CVD has been well established through epidemiological and clinical studies [20, 21,22,23]. The protective roles of HDL cholesterol from CVD have been suggested to occur in various ways [21,24,25]. HDL exerts part of its anti-atherogenic action by counteracting LDL oxidation. Recent studies reveal that HDL promotes the reverse cholesterol transport pathway, by inducing removal of excess accumulated cellular cholesterol resulting in prevention of the generation of an oxidative modified LDL [22,26,27]. Furthermore, HDL inhibits the oxidation of LDL by transition metal ions, but also prevents 12-lipoxygenase-mediated formation of lipid hydroperoxides [28,29,30,31,32]. After oral administration of ethanol extract of *Cassia angustifolia* for a 28 days period, there was no change in the level of LDL, cholesterol and triglyceride suggesting that the plant has fewer tendencies to induce atherosclerotic plaque, while high level of HDL indicates that it may be useful in managing cardiovascular diseases. Histological evaluation revealed that there was little to no damage to the membrane and other part of the heart. This agrees with biochemical parameters that the plant maybe of cardiovascular benefit to human.

CONCLUSION

The result of the study suggests that *Cassia angustifolia* may be of benefit in managing dyslipidemia. Further study can be carried out to determine its effect on cardiovascular condition such as hypertension, cardiac arrhythmia, angina, etc.

Acknowledgement

The authors wish to appreciate everyone who has contributed to the success of this work.

REFERENCES

1. Jude EO, Joseph OS, and Emem EU. Hepatoprotective activity of the extract of *Homalium letestui stem* against paracetamol induced liver injury. *Avicenna Journal of Phytomedicine*. 2017. 7(1): 27–36.
2. Zhu M, Lew KT and Leung P. Protective effect of plant formula on ethanol induced gastric lesions in rats. *Phytotherapy Research*. 2002. 16: 276-280.
3. Sofowora EA. Medicinal Plants and Traditional Medicine in Africa 1st edition, Spectrum Books Ltd. Ibadan, Nigeria. 1989. Page 142-156.
4. Izzo A. Drug interactions with St. John's Wort (*Hypericum perforatum*): A review of the clinical evidence. *International Journal of Clinical Pharmacology and Therapeutics*. 2004. 42:139-148.
5. Seth SD and Sharma B. Medicinal plants in India. *Indian Journal Medical Research*. 2004. 120:9-11.
6. Oyepata SJ, Jude EO and Opeyemi TJ. Hepatoprotective activity of extract of *Homalium Letestuistem* against carbon tetrachloride-induced liver injury. *Advanced Herbal Medicine*. 2018. 3(4): 1-11.
7. Joseph OS, Builders M, Emem EU. and Joseph OT. Effect of ethanol leaf extract of *cassia angustifolia* extract on kidney of wister rats. *Global Scientific Journal*: 2019. Volume 7, Issue 10. Page 106-122.
8. Hokche O, Berry PE and Huber O. Nuevo Catálogo de la Flora Vascular de Venezuela. Fundación Instituto Botánico de Venezuela. 2008. 1-859.
9. Figueiredo E and Smith GF. Plants of Angola. *Strelitzia National Botanical Institute, Pretoria*. 2008. 22:1-279.
10. Joseph OS, Builders M, Emem EU. and Joseph OT. Effect of ethanol leaf extract of *cassia angustifolia* extract on kidney of wister rats. *Global Scientific Journal*. 2019. Volume 7, Issue 10. Page 343-359.
11. Hariyadi B. and Ticktin T. Uras: Medicinal and ritual plants of Serampas, Jambi Indonesia. *Ethnobotany Research and Applications*. 2012. vol. 10, pp. 133–149.
12. Van Viet B, Chage L, Vladan L, Schnyder-Candrian S and Montani S. Direct and indirect methods used to study arterial blood pressure, *Journal of Pharmacology and*

- Toxicology Methods*. 2008. vol. 44, no. 2, pp. 361–373.
13. Gornall A, Bradwill C and David M. Determination of serum proteins by means of the biuret reaction. *Journal of Biology and Chemistry*. 1994. vol. 77, pp. 167–182.
 14. Wilbur KM, Bernheim F and Shapiro O. Determination of lipid peroxidation. *Archives of Biochemistry and Biophysics*. 1949. vol. 24, pp. 3959–3964.
 15. Misra H and Fridovich I. (1972). Determination of the level of superoxide dismutase in whole blood, Yale University Press New Haven.
 16. Savage EJ, Msyamboza K, Gies S, D'Alessandro U, Brabin BJ. Maternal anemia as an indicator for monitoring malaria control in pregnancy in sub-Saharan Africa. *BJOG*. 2007. 1222 – 1231.
 17. Steketee RW, Nahlen BL, Parise ME, Menendez C. The burden of malaria in pregnancy in malaria-endemic areas. *Am J Trop Med Hyg*. 2001. 64: 28 – 35.
 18. Merzouki A, Ed-Derfoufi F, El-Aallal A, Molero-Mesa J. Wild medicinal plants used by local Bouhmed population (Morocco). *Fitoterapia*. 1997. LXVIII 5: 444–460.
 19. Hahlbrock K. Flavanoids. from *Apium petroselinum* seeds. *National Academic Science Letter* 4. 1981. 249–251.
 20. Simon JE, Quinn J. Characterization of essential oil of parsley. *Journal of Agriculture Food and Chemistry*. 1988. 36: 467–471.
 21. Francis GW, Isaksen M. Droplet counter current chromatography of the carotenoids of parsley *Petroselinum crispum*. *Chromatographia*. 1989. 27: 549–551.
 22. Lamarti A, Badoc A, Bouriquet R. A chemotaxonomic evaluation of *Petroselinum crispum* (Mill.) A. W. Hill (parsley) marketed in France. *Journal of Essential Oil Research*. 1991. 3: 425–433.
 23. Spraul MH, Nitz S, Drawert F. The chemical composition of parsley root and seed extracts. *Chem Microbiol Technol Lebensm*. 1991 13: 179–182.
 24. Davey MW, Bauw G, Montagu MV. Analysis of ascorbate in plant tissue by high performance capillary zone electrophoresis. *Anal Biochemistry*. 1996. 239: 8–19.
 25. Cohen AM, Yanko L, Rosenmann E. Control of blood glucose levels and development of diabetic microangiopathy: Effect of glibornurid. *Journal of Medical Sciences*. 1998. 19: 311–8.
 26. Relander A, Raiha CE. Differences between the enzymatic and toluidine methods of blood glucose determination. *Scandinavian Journal of Clinical Laboratory Investigation*. 1963. 15: 221–224.
 27. Beuge JA, Aust SD. Microsomal lipid peroxidation. *Methods in Enzymology*. 1978. 52: 302–311.
 28. Beutler E. Glutathione in red blood cell metabolism. *A Manual of Biochemical Methods*, Grune & Stratton, New York. 1975; pp 112–114.
 29. Aiello LP, Wong J.S. Role of vascular endothelial growth factor in diabetic vascular complications. *Kidney International* 58 (Suppl 77). 2000. 113–119.
 30. Shah G, Pinnas JL, Lung CC, Mahmoud S, Mooradian AD. Tissue specific distribution of malondialdehyde modified proteins in diabetes mellitus. *Life Science*. 1994. 55(17): 1343–1349.
 31. Fukui T, Noma T, Mizushige K, Aki Y, Kimura S, Abe Y. Dietary troglitazone decreases oxidative stress in early stage type II diabetic rats. *Life Science*. 2000. 66 (21): 2043–2049.
 32. Rauscher FM, Sanders RA, Watkins JB. Effects of new antioxidant compounds PNU-104067F and PNU-74389G on antioxidant defense in normal and diabetic rats. *J Biochemistry of Molecular Toxicology*. 2000. 14(4): 189–194.