

## Research Article

## Some Nephrotoxic Effects of Commonly Used Mosquito Repellents in Sokoto State, Nigeria

Khadijah, A.A.<sup>1</sup>, Gamde, S.M.\*<sup>1</sup>, Hauwa, K.<sup>1</sup>, Perede, A.<sup>2</sup>, Musa, A.A.<sup>3</sup>, Aisha, A.<sup>3</sup>, Dansy, A.D.<sup>1</sup> & Aminu, G<sup>2</sup>

<sup>1</sup>Hospital Services Management Board, Department of Medical Laboratory Services, Sokoto, Nigeria

<sup>2</sup>Sokoto Specialist Hospital, Medical Laboratory Services, Sokoto State, Nigeria

<sup>3</sup>Usman Danfodiyo University Teaching Hospital Sokoto, Department of Histopathology, Nigeria

### Article History

Received: 11.05.2020

Accepted: 29.05.2020

Published: 09.06.2020

### Journal homepage:

<https://www.easpublisher.com/easjms>

### Quick Response Code



**Abstract:** Mosquito repellents are used extensively in Nigeria to prevent mosquito and diseases associated with them. Most active constituents of repellents are well known for their toxicities. The purpose of this study was to determine the nephrotoxic effects of Rambo and Sharp mosquito repellents commonly used in Sokoto State, Nigeria. Exposure of 27 Wistar rats to Rambo and Sharp mosquito repellents for 5 min per day over a period of 21 days induced interstitial haemorrhage, glomerular and tubular degenerations. Glomerular damage is characterized by shrunken glomeruli and widening of bowman space. Sharp repellent containing 70% dichlorvos was the most injurious insecticide. Therefore, repeated exposures to mosquito repellents are deleterious to the kidney.

**Keywords:** Transfluthrin; Permethrin; Dichlorvos; Wistar rats; Kidney; Histopathology.

**Copyright @ 2020:** This is an open-access article distributed under the terms of the Creative Commons Attribution license which permits unrestricted use, distribution, and reproduction in any medium for non commercial use (NonCommercial, or CC-BY-NC) provided the original author and source are credited.

## INTRODUCTION

Malaria is a major public health problem in Nigeria, accounting for more cases of infection and deaths than other countries worldwide. The extent of repeated exposure to different residual insecticides may contribute to the existing burden of malaria (Saidu *et al.*, 2015). Natural pyrethrins and synthetic pyrethroids are the most common household insecticides used to repel or kill mosquito, and are well known for their toxicities on tissue organs (Moya-Quiles *et al.*, 1995).

Among popular made in Nigeria products of mosquito repellents are the Rambo and Sharp mosquito repellents. Passagne *et al.* (2012) and Wardoyo *et al.* (2018) reported that chemical repellents caused pathological changes similar to cyanide and aldehyde. The Rambo repellent is composed of 0.25% transfluthrin and 0.20% permethrin, manufactured by Gongoni Company Limited Nigeria. Wardoyo *et al.* (2018) and Unggul *et al.* (2019) reported its transfluthrin content to induced acute tubular and glomerular necrosis in mice.

Sharp repellent is another made in Nigeria product, composed of 70% dichlorvos, manufactured by

Onitsha Company Nigeria. Somia *et al.* (2012) and Tela *et al.* (2016) reported that dichlorvos induced tubular vascular degeneration and lumen dilatations in mice. Furthermore, Olatunde *et al.* (2014) reported glomerular congestion in dichlorvos induced morphological alteration in rats. Each of these insecticides targeted and elicits specific response on insect nerve cells in similar manner that their little mists exert the required effects (Miao *et al.*, 2017).

Although, most repellent substances are metabolized in mammals, chronic exposure through inhalation, ingestion or dermal absorption could cause serious tissue damage (Mamuna *et al.*, 2019). Human exposure is mainly through inhalation of household vaporizing units of repellents (WHO 1989). Repellent particles in the pulmonary lungs are carried via blood to the kidney for filtration. The kidneys function to produce urine from the body's metabolic processes and it is the main path of toxic substances (toxins). Thus, the anatomy and physiology of the kidney are predisposed to numerous toxins (Unggul *et al.*, 2019).

Despite multiple scientific reports on the toxicities of different individual mosquito preparations on the kidney, there is no current study on the

nephrotoxic effects of Rambo and Sharp mosquito repellents commonly used in Sokoto State, Nigeria. This study would increase our knowledge on transfluthrin, permethrin and dichlorvos on the structures and functions of the kidney.

## MATERIALS AND METHODS

### Ethical issues

The Institutional Animal Ethics Committee approved the permission for the use of laboratory animals in Pharmacology Department, Usmanu Danfodiyo University Sokoto, Nigeria.

### Test mosquito chemical repellents

Test mosquito repellents were purchased from a retail outlet in Diplomat area of Sokoto South, Nigeria. The Rambo mosquito repellent contents are 0.25% transfluthrin and 0.20% permethrin, manufactured by Gongoni Company Limited Nigeria, and Sharp mosquito repellent composed of 70% dichlorvos, manufactured by Onitsha Company Nigeria.

### Experimental animals

A total of twenty seven (27) adult male and female Wistar rats, weighing 150-180 grams were used in the experiment. Animals were procured from the Animal House of Ahmadu Bello University Zaria, Kaduna State, Nigeria. Animals were kept in well ventilated room with optimum environmental conditions of temperature (22 ± 2°C) with 12 hours dark/light cycle. The animals were fed with standard pellets and tap water *ad libitum* and were allowed to acclimatize for two weeks before the experiment.

### Experimental Design

We used 27 Wistar rats that were divided into three groups: a control group, a treatment group with Rambo and Sharp mosquito repellents. The control group was unexposed to repellents. The treatment groups were exposed to Rambo repellent composed of 0.25% transfluthrin and 0.20% permethrin, and to 70% dichlorvos constituents of Sharp repellent respectively. Animals were exposed in an enclosed chamber with dimension of 53.5 cm x 39.5 cm for 5 minutes in 21 days.

**Table 1:** A table showing the different mosquito repellents dose and duration of exposure with corresponding control (n=9)

Mosquito repellents	Dose..... (5min/day)	Types...	Period of animal exposure		
			Week 1	Week 2	Week 3
--	None	---	3 rats	3 rats	3 rats
Rambo	0.45ml/w	Liquid	3 rats	3 rats	3 rats
Sharp	0.45ml/w	Liquid	3 rats	3 rats	3 rats

### Tissue preparation

#### Statistical analysis

SPSS 23.0 version software was employed for this analysis. Data entry was done using Microsoft excel version 13 and Shapiro-Wilk test was used to verify the distribution of the obtained data. In order to assess if the data was parametric or nonparametric distribution, results were presented as mean and standard deviation (SD). Two-way analysis of variance (ANOVA) was conducted with Bonferoni adjustment post hoc test to compare parameters within experimental animals and  $P \leq 0.05$  was considered statistically significant.

**Table 2:** Body weights of animals at pre-and post-exposure to mosquito repellents (n=9)

Durations of exposure	Normal control	Rambo repellent	Sharp repellent
<b>7 days</b>			
Pre-exposure	141.67±6.36	156.00±11.02	139.33±13.17
Post-exposure	158.67±12.1	158.00±9.71	131.33±7.22
<b>14 days</b>			
Pre-exposure	138.00±15.5	174.33±11.77	162.33±5.49
Post-exposure	104.00±52.2	177.33±1.45	162.00±4.16
<b>21 days</b>			
Pre-exposure	162.33±14.2	174.33±9.33	181.33±12.44
Post-exposure	119.33±59.6	181.33±10.81	188.00±11.79

## RESULT

The animals from treatment and control

### Morbidity and mortality

The exposure of animals to test mosquito repellents for 5 minutes per day over a period of 21 days did not cause mortality. However, animals showed behavioural signs of toxicity including irritations, ruffled fur appearance, lethargy.

### Relative Body Weight

There was no significant change in the body weight of experimental animals exposed to the different mosquito repellents compared to the normal control (Table 2,  $P \geq 0.05$ ). Body weights of animals were not statistically significant ( $P \geq 0.05$ ).

### Histopathological Result

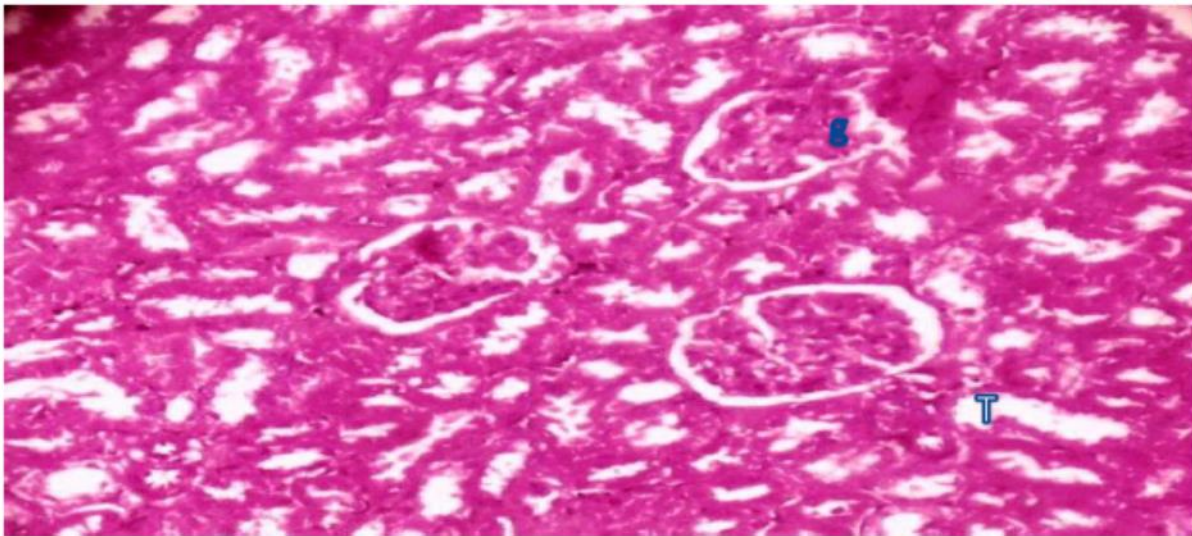
Repeated exposure of animals to Rambo and Sharp repellents induced interstitial haemorrhage, glomerulus and tubular degenerations (Fig.4,6).

Glomerular damage is characterized by shrunken glomeruli and widening of Bowman space (Fig.4,6,7).

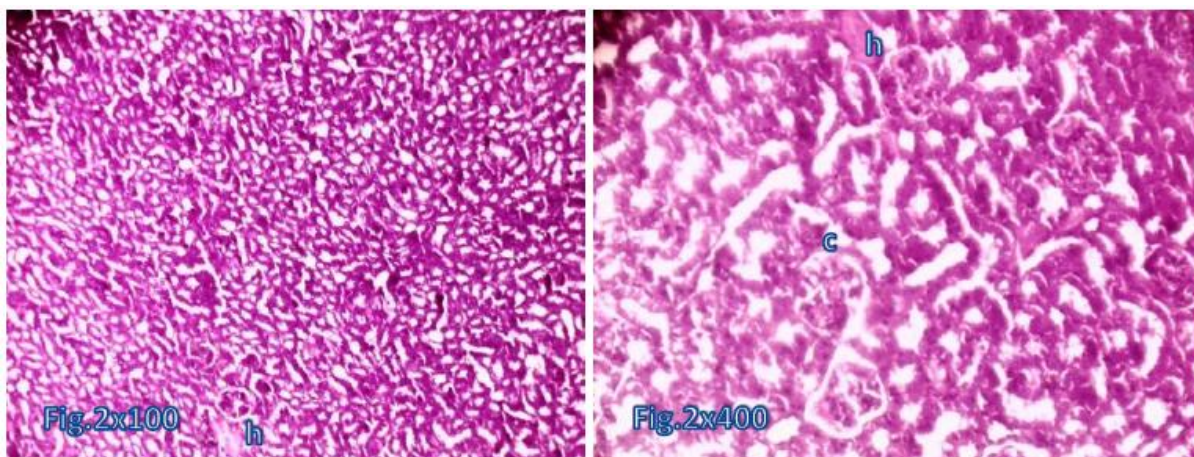
Tubular damage is characterized by narrowing of the tubular lumen, interbrided tubules and interstitial haemorrhage (Fig.4,6). Progressive



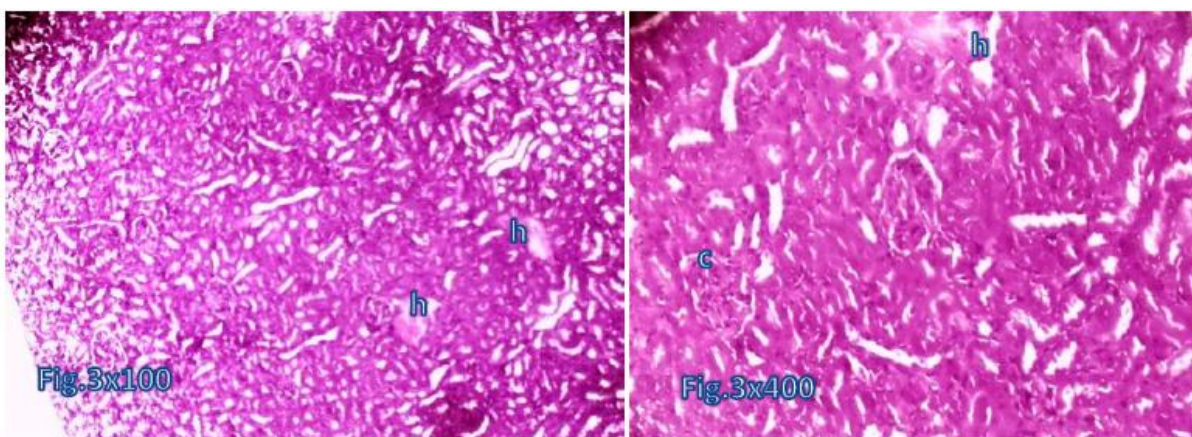
glomerular and tubular damage caused tissue necrosis (Fig.4,7).



**Fig.1:** Normal control of animals showed normocellular glomerular tufts (g) in a background of tubules (t) with cuboidal cell epithelial lining. (H&E. x 400).

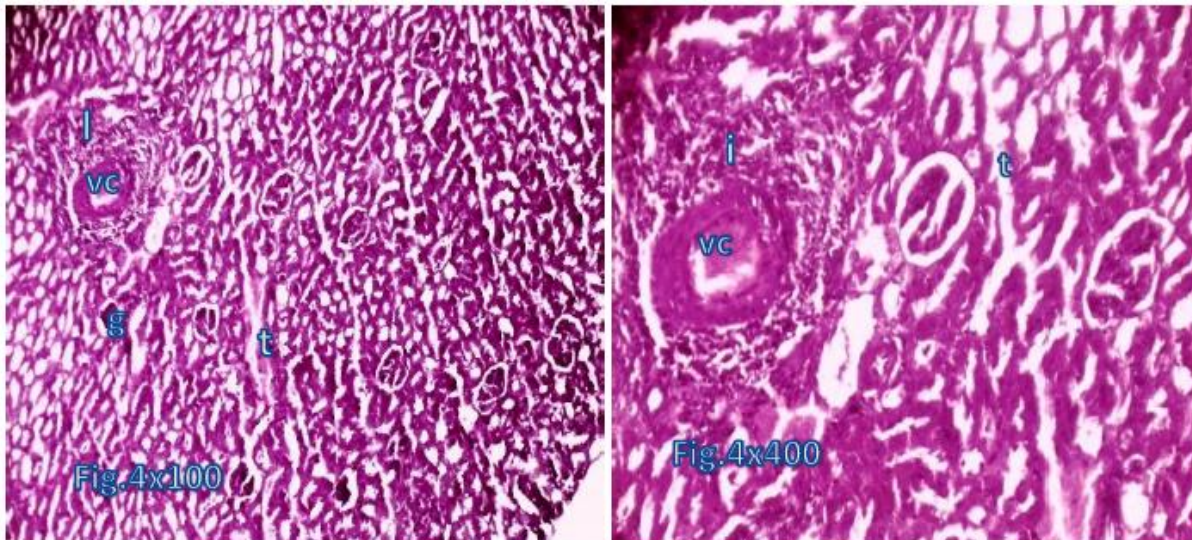


**Fig.2:** Kidney exposed to Rambo mosquito repellent containing 0.25% transfluthrin and 0.20% permethrin for 7 days showed cortical haemorrhage (h) and congestion around bowman's space (c). (H&E. x 100,400).

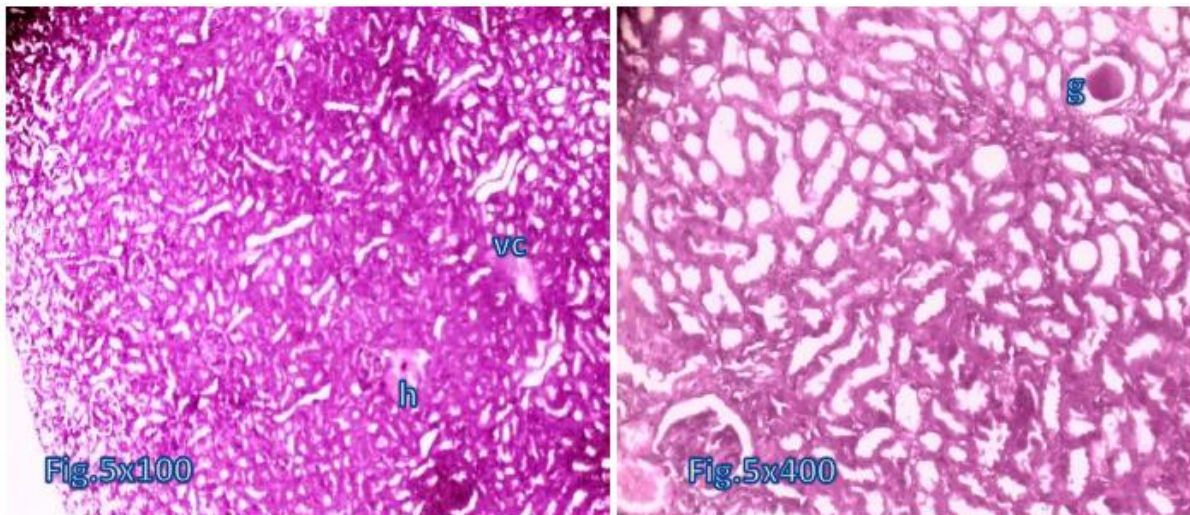


**Fig.3:** Kidney exposed to Sharp mosquito repellent containing 70% dichlorvos for 7 days showed cortical haemorrhage (h) and congestion around bowman's space (c). (H&E. x 100,400).

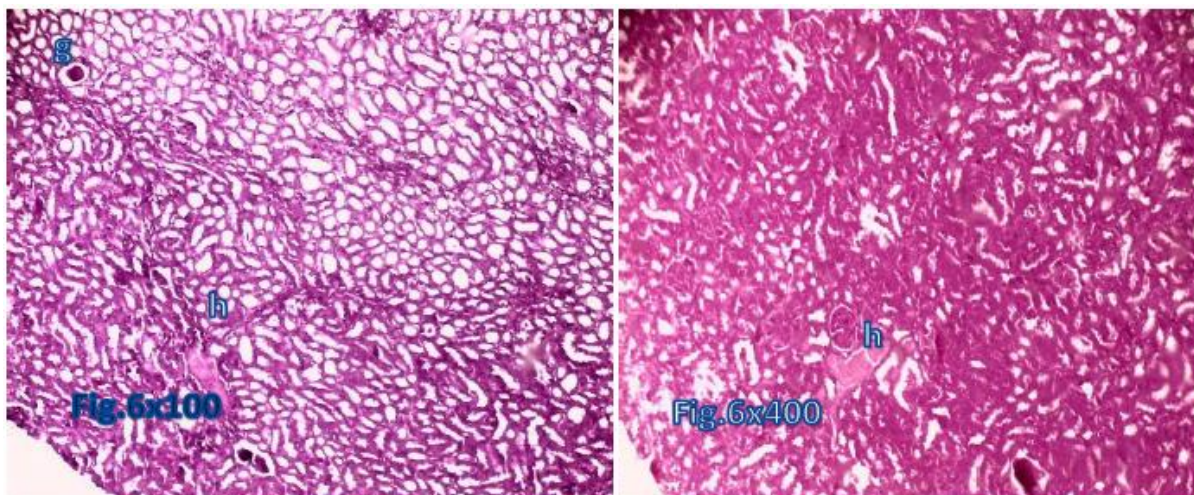




**Fig.4:** Kidney exposed to Rambo mosquito repellent containing 0.25% transfluthrin and 0.20% permethrin for 14 days showed hyper cellularity (I) around congested blood vessel (vc), shrunken/degenerated glomeruli (g) with bridged renal tubules (t). (H&E. x 100,400).

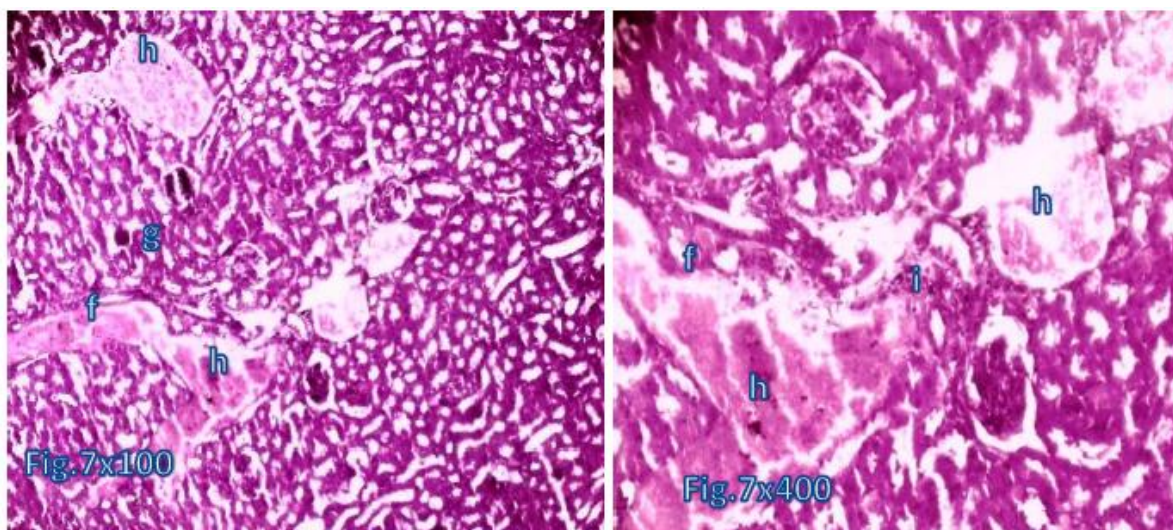


**Fig.5:** Kidney exposed to Sharp mosquito repellent containing 70% dichlorvos for 14 days showed congested blood vessel (vc), interstitial haemorrhage, and shrunken glomerulus (g). (H&E. x 100,400).



**Fig.6:** Kidney exposed to Rambo mosquito repellent containing 0.25% transfluthrin and 0.20% permethrin for 21 days showed degenerated glomeruli (g), and interstitial haemorrhage (h). (H&E. x 100,400).





**Fig.7:** Kidney exposed to Sharp mosquito repellent containing 70% dichlorvos for 21 days showed congested blood vessel, interstitial haemorrhage (h), glomerular and tubular necrosis (f). (H&E. x 100,400).

## DISCUSSION

We designed this study to evaluate the nephrotoxic effects of commonly used Rambo and Sharp mosquito repellents in Sokoto State, Nigeria. No mortality was recorded on 21 days exposure except irritations, ruffled fur appearance, and lethargy on Wistar rats. The studies of Naikanishi *et al.*, 1970;Somia *et al.*, 2013;Mamuna *et al.*, 2019 reported similar toxicity as irritations, ruffled fur appearance, and lethargy in both experimental animals and humans exposed to mosquito repellents.

We observed that the body weight loss of animals exposed to repellents though not significant agrees with previous reports on insignificant weight change following inhalation of mosquito repellents (Table 2,  $P \geq 0.05$ ) (Schoenig 1995;Ishmael *et al.*, 1998;Abubakar *et al.*, 2007;Garba *et al.*, 2007).

We observed that both Rambo and Sharp mosquito repellents manufactured in Nigeria, induced histopathological changes on kidney organs. The kidney cell damage was demonstrated in the glomeruli and tubules (Fig.2,3,4,5,6,7). The shrunken glomerular (g) and fibrotic tubules indicated structural damage known as the glomeruli and tubular damage. The glomerular damage was characterized by widening of Bowman space due to shrunken glomeruli (Fig.4,5,6,7). The tubular damage is characterized by narrowing of the tubular lumen. Glomerular and tubular damage unabated progressed to tissue necrosis or cell death (Fig.4,6), a pathological condition called Acute Tubular Necrosis (ATN). Sarkar *et al.* (2011);Momeni *et al.* (2017) and Unggul *et al.* (2019) reports corroborated our finding on nephrotoxic ATN caused by toxic repellent substances in cells. Somia *et al.* (2012) and Tela *et al.* (2016) reported similar toxic effects of dichlorvos on kidney. Furthermore, Taiwo *et al.* (2008)

and Emmanuel *et al.* (2013) reported glomerular and tubular degeneration, necrosis, and vasculitis to mosquito fumes in experimental rats. Garba *et al.* (2007) and Mamuna *et al.* (2019) reported multifocal congestion, cystic dilation in the medulla and tissue necrosis similar to our finding. The volatile organic substances of repellents with free radicals induced significant tissue damage (John and John 2015).

Our finding indicates deleterious health consequences of mosquito repellents on human kidney in case of long time exposure. Hence, standard regulations need to be popularized among users, especially those in rural areas by educating the general masses health implications of frequent exposure to mosquito repellents and manufacturers to specify the ingredients used with scientific references regarding its safety and duration of use.

## CONCLUSION

The results of the research showed damaged kidney organs to Rambo and Sharp repellents exposure. The transfluthrin, permethrin and dichlorvos in Rambo and Sharp repellents induced renal damage. Sharp repellent with 70% dichlorvos induced more severe damage to the kidney. However, more dosage of active constituents could cause more damage to organs.

**Conflict of Interest:** None

## REFERENCES

1. Abubakar, M. G., & Hassan, L. G. (2007). Toxicological effects of some mosquito coil brands in experimental rats. *Internet J Toxicol*, 4, 1-6.
2. Garba, S. H., Adelaiye, A. B., & Mshelia, L. Y. (2007). Histopathological and biochemical changes in the rats kidney following exposure to a

- pyrethroid based mosquito coil. *Journal of Applied Sciences Research*, 3(12), 1788-1793.
3. Gul, S., Ibrahim, S., Wasif, N., Zafar, A., & Syed, R. (2013). Mosquito repellents: killing mosquitoes or yourselves. *J Sci Innovative Res*, 2(6), 1052-1057.
  4. Ishmael, J., & Litchfield, M. H. (1988). Chronic toxicity and carcinogenic evaluation of permethrin in rats and mice. *Toxicological Sciences*, 11(1), 308-322.
  5. John, N. A., & John, J. (2015). Prolonged use of mosquito coil, mats, and liquidators: a review of its health implications. *International Journal of Clinical and Experimental Physiology*, 2(4), 209-213.
  6. Juswono, U. P., Wardoyo, A. Y. P., Widodo, C. S., Andoyo, J., & Noor, E. (2019). The Effects Of Transfluthrin As The Active Substance Of One Push Aerosol Repellent On Organs Damage Of Mice (Mus Musculus)(Case Study Of Lung, Liver, Bloods, And Kidney). *International Journal*, 16(55), 113-118.
  7. Miao, J., Wang, D., Yan, J., Wang, Y., Teng, M., Zhou, Z., & Zhu, W. (2017). Comparison of subacute effects of two types of pyrethroid insecticides using metabolomics methods. *Pesticide biochemistry and physiology*, 143, 161-167.
  8. Momeni, H. R., & Eskandari, N. (2017). Effect of curcumin on kidney histopathological changes, lipid peroxidation and total antioxidant capacity of serum in sodium arsenite-treated mice. *Experimental and toxicologic pathology*, 69(2), 93-97.
  9. Moya-Quiles, M. R., Muñoz-Delgado, E., & Vidal, C. J. (1995). Effect of the pyrethroid insecticide allethrin on membrane fluidity. *Biochemistry and molecular biology international*, 36(6), 1299-1308.
  10. Naikanishi, M. (1970). Toxicological studies on a new pyrethroid: Kikuthrin. Part I. Studies on insecticide V. *Botyu-Kagaku*, 35, 103-112.
  11. Naz, M., Rehman, N., Ansari, M. N., Kamal, M., Ganaie, M. A., Awaad, A. S., & Alqasoumi, S. I. (2019). Comparative study of subchronic toxicities of mosquito repellents (coils, mats and liquids) on vital organs in Swiss albino mice. *Saudi Pharmaceutical Journal*, 27(3), 348-353.
  12. Owoeye, O., Edem, F. V., Akinyoola, B. S., & Arinola, G. O. (2014). Renal Corpuscles Were Protected From Dichlorvos-Induced Morphological Alterations in Rats by Antioxidant Vitamins. *International Journal of Morphology*, 32(2), 475-480.
  13. Passagne, I., Morille, M., Rousset, M., Pujalté, I., & L'azou, B. (2012). Implication of oxidative stress in size-dependent toxicity of silica nanoparticles in kidney cells. *Toxicology*, 299(2-3), 112-124.
  14. Saidu, A. Y., Sadiya, H., Dikwa, M. A., Abubakar, M. M., Fana, S. A., & Nuraddeen, M. B. (2015). Detection of plasmodium species among pregnant women attending antenatal care. *IOSR Journal of Dental and Medical Science*, 14(11), 61-66.
  15. Sarkar, A., Das, J., Manna, P., & Sil, P. C. (2011). Nano-copper induces oxidative stress and apoptosis in kidney via both extrinsic and intrinsic pathways. *Toxicology*, 290(2-3), 208-217.
  16. Schoenig, G.P. (1995). Mammalian Toxicology of Pyrethrum Extract in Pyrethrum Flowers: Production, Chemistry, Toxicology and Uses. Casida, I.E and G.B. Quistad (Eds.). New York. Oxford University Press, Pp. 249-257.
  17. Taiwo Idowu, E., Aimufua, O. J., Yomi-Onilude, E., Akinsanya, B., & Adetoro Otubanjo, O. (2013). Toxicological effects of prolonged and intense use of mosquito coil emission in rats and its implications on malaria control. *Revista de biologia tropical*, 61(3), 1463-1473.
  18. Taiwo, V. O., Nwagbara, N. D., Suleiman, R., Angbashim, J. E., & Zarma, M. J. (2008). Clinical signs and organ pathology in rats exposed to graded doses of pyrethroids-containing mosquito coil smoke and aerosolized insecticidal sprays. *African journal of biomedical research*, 11(1), 97-104.
  19. Tela I.A, Sagir M.S. (2016). *Journal of Harmonized Research in Medical & Health Sciences*, 3(3), 180-187.
  20. Wardoyo A. Y. P., Juswono U. P., & Noor j. A. E. (2018). Varied dose exposures to ultrafine particles in the motorcycle smoke cause kidney cell damages in male mice. *Toxicol. Reports*, 5, 383-389.
  21. Wolansky, M.J., & Harrill, J.A. (2008). Neurobehavioral toxicology of pyretheroid insecticides in adult animals: a critical review. *Neurotoxicol Teratol*, 30(2), 55-78.
  22. World Health Organization (WHO). (1989). Environmental Health Criteria. Dichlorvos. World Health Organization.