



A Rare Case of Duodenal Atresia with Situs Inversus Abdominalis

Hassan Shehu ^a, Marcia Ihekaike ^a, Maryam Shehu ^a, Daniel Momoh ^b
and Edwin Oseni-Momodu ^a

^a Bingham University, Bingham University Teaching Hospital, Jos, Nigeria.
^b Bingham University Teaching Hospital, Jos, Nigeria.

Authors' contributions

This work was carried out in collaboration among all authors. All authors read and approved the final manuscript.

Article Information

Open Peer Review History:

This journal follows the Advanced Open Peer Review policy. Identity of the Reviewers, Editor(s) and additional Reviewers, peer review comments, different versions of the manuscript, comments of the editors, etc are available here: <https://www.sdiarticle5.com/review-history/83974>

Received 23 December 2021

Accepted 03 March 2022

Published 05 March 2022

Case Report

ABSTRACT

Background: Duodenal atresia is one of the causes of intestinal obstruction in a new-born. It can be associated with other congenital anomalies such as intestinal malrotation and congenital heart diseases. Association of duodenal atresia with situs inversus abdominalis is extremely rare. It is characterised by bilious or non-bilious vomiting within 24 to 38 hours of neonatal life, typically following the first oral feeding.

Case Report: A ten hour old male neonate delivered at 37 weeks presented with bilious vomiting. There was polyhydramnios in third trimester. There was no abdominal distension, no meconium passed at 48hrs, and systemic review was normal. On examination, he was febrile and tachypnoeic. His naso-gastric tube drained bilious effluent and bowel sounds were absent. He had a grade 3 systolic murmur at the left lower sternal border. A plain abdominal radiograph revealed a reverse double-bubble sign without dextrocardia. Echocardiography revealed a congenital mitral incompetence. Based on these findings, diagnosis of duodenal atresia with situs inversus abdominalis and congenital heart disease was made. The child had a laparotomy with intraoperative findings of type 3 duodenal atresia, dilated stomach and proximal duodenal segment, complete situs inversus abdominalis, polysplenia, intestinal malrotation and midgut volvulus. He had Kimura diamond duodeno-duodenostomy, Ladd's procedure and a transgastric, transanastomotic tube was passed. He stoolled and breast feeding commenced via transgastric transanastomotic tube on third and fourth postoperative days respectively. He did well and was discharged to go home.

*Corresponding author. E-mail: maryamshshu1405@gmail.com;

Conclusion: It is of utmost importance to look out for congenital anomalies when evaluating patients with duodenal atresia. This case reiterates the significance of reverse double bubble sign as an important preoperative means of recognizing this condition.

Keywords: Duodenal atresia; reverse double-bubble sign; situs inversus abdominalis.

1. INTRODUCTION

Duodenal atresia is a common intestinal atresia treated by paediatrics surgeons and it occurs in 1: 5000-10,000 live births, more common in boys than girls. More than 50% of affected patients have associated congenital anomalies [1-2]. Situs inversus is a rare condition with a frequency of about 1 in 10,000 of the normal population [3]. Duodenal atresia is associated with Down's syndrome (30%), annular pancreas (23%), congenital heart disease (22%), malrotation (20%), oesophageal atresia (8%), others (20%) [4]. Furthermore, it can be part of the VACTERL complex of anomalies (vertebral, anorectal, cardiac, oesophageal atresia, renal, and limb anomalies); prematurity 45%; growth retardation 33%; other intestinal anomalies, 25% [1,5]. There is a rare association of duodenal atresia with situs inversus abdominalis, about 20 cases have been reported in the literature so far [6].

Neonates with duodenal atresia only, without complex congenital anomalies have good prognosis. The survival rate for duodenal atresia is said to be between 90-95%. The factors that lead to bad prognosis are prematurity and multiple congenital anomalies [7].

2. CASE REPORT

A ten hour old male neonate presented with bilious vomiting usually after feeding since birth. He was delivered by caesarean section at 37 weeks gestation to a 38 year old Para 3 mother and weighed 2.5kg at birth. An ultrasonography done at 36 weeks of gestation revealed polyhydramnios. The pregnancy was otherwise uneventful. The father is a 45 year old civil servant, mother is a housewife. There is no history of congenital anomalies in the family, the parents' marriage is non-consanguineous.

Physical examination revealed a febrile baby with an axillary temperature of 37.8°C who was not dehydrated. The pulse rate was 140 beats per minute, which was regular and normal volume. He had normal 1st and 2nd heart sounds with a grade 3 systolic murmur heard at the left lower sternal border. He was tachypneic with a

respiratory rate of 80 cycles per minute but had equal chest expansion and good air entry bilaterally with a baby saturating at 94% in room air. His abdomen was full with marked epigastric fullness and moved with respiration. There were no areas of tenderness and no palpable organomegaly. His bowel sounds were absent; his anus was patent and normally placed with a good sphincteric tone. He had normal male external genitalia. He was placed on nil per oral, commenced on intravenous fluid for hydration at maintenance. He was also placed on intravenous antibiotics and had a nasogastric tube passed for gastric decompression. 60ml of bilious effluent was obtained, hence the need for continuous nasogastric tube drainage. He had not passed meconium by the fifth day of life.

The investigation results: As part of workup for the clinical diagnosis of a congenital intestinal obstruction, he had a plain abdominal radiograph done which showed a reversed double bubble sign without dextrocardia (Fig. 1). Based on this, a diagnosis of duodenal atresia with situs inversus abdominalis was made. He also had an echocardiography done which revealed that the anterior mitral valve leaflet was elongated and prolapsed under the posterior leaflet. There was also minimal excursion of the posterior mitral leaflet and significant mitral incompetence with a jet length of about 2.4cm into the left atrium. Other supportive investigation results are: Full Blood Count (WBC)-9,000, PCV-36%, platelets-218, Neutrophil-58%, Lymphocytes-38%, Monocytes-03%, Basophils-01%
Urea & Electrolyte - BUN-2.2mmol/L↔, Cr- 27-µmol/L. Na- 117mmol/L↓, K+-3.3 mmol/L ↓, Cl- 111mmol/L↓, HCO₃ - 16mm/L↓

Following correction of the deranged electrolytes, stabilisation and optimization; he had a laparotomy done on the fifth day of life. The intraoperative findings (Fig. 2,3,4) were that of clear peritoneal fluid, dilated stomach and proximal duodenal segment, collapsed distal duodenum and small bowel (type 3 duodenal atresia), complete situs inversus abdominalis, intestinal malrotation, midgut volvulus and polysplenia. He then had Kimura diamond shaped duodenoduodenostomy, release of

Ladd's band, without appendectomy, and a transgastric transanastomotic tube was passed.

Post operatively, he had nasogastric drainage until he passed stools on the 3rd day post-op, after which feeling commenced on the 4th day

after surgery. He tolerated food and made a full recovery. He was discharged to go home and seen for follow up to assess his wound healing and adequacy of nutrition two weeks after discharge. He was then subsequently referred to a paediatric cardiologist for follow up.

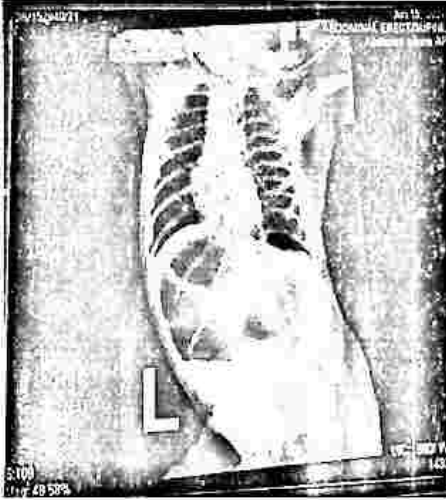


Fig. 1. Reversed double bubble sign

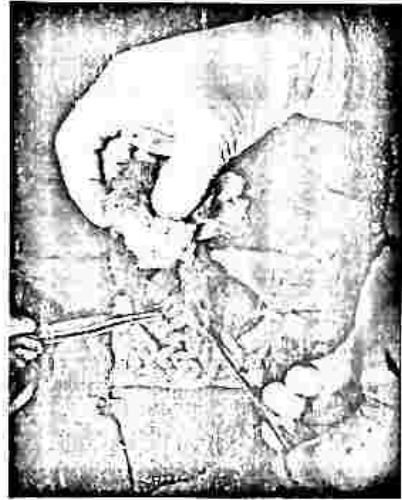

Fig. 2. Type 3 Duodenal atresia

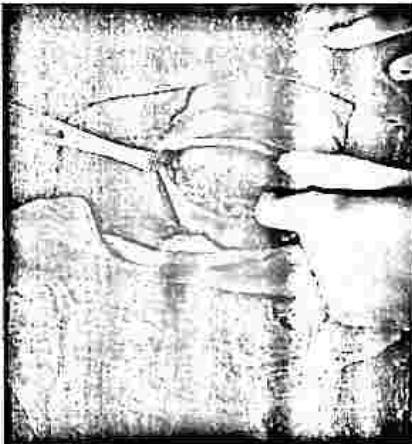

Fig. 3. Polysplenia in the right hypochondria

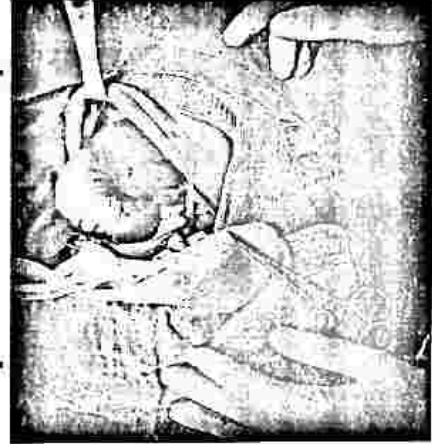

Fig. 4. Liver in the left hypochondria

3. DISCUSSION

The patient presented with a history of billous vomiting and delayed passage of meconium, that is usually the commonest presenting symptoms of neonates with duodenal atresia [7]. However, Ademola et al in their case reported the passage of meconium by their patient which is in contrast to our patient [8]. The patient had duodenal atresia and situs inversus abdominalis, which is a rare occurrence. This is similar to the few studies

that reported duodenal atresia and situs abomonis totalis just like the index patient [9-11]. In keeping with other literature, occurrence of polysplenia seen on the right was also seen in our patient [9-11].

Duodenal atresia can take many forms, but proximal and distal intestinal segments always end blindly [12]. In the Type 3, the proximal and distal segments of the duodenum are completely separated as was found in the index case [13].

Duodenal obstructions can be complete or partial. Our index patient had a complete obstruction with a gap between the proximal and distal segments. Intrinsic duodenal obstructions may be attributed to atresia or mucosal webs. Duodenal extrinsic obstruction can occur in association with malrotation or a pre-duodenal portal vein. Hallmarks of duodenal atresia are a dilated proximal segment and a decompressed distal segment.

Duodenal obstruction is characterized by a double-bubble sign on prenatal ultrasonography. The first bubble corresponds to the stomach and the second to the post-pyloric dilated duodenum [14]. It is important to note that prenatal ultrasonography does not reliably detect duodenal atresia as was the case in the index patient. This is because in the presence of fetal vomiting, fetuses with duodenal atresia may have normal ultrasonographic findings. Prenatal diagnosis would have allowed for prenatal counseling of the mother and planning of management. Polyhydramnios was, however, detected in the maternal antenatal ultrasonography of the index case. Difficulty in swallowing like in oesophageal atresia or a blockage of the foetus' gastrointestinal tract like in duodenal atresia and stenosis can lead to polyhydramnios.

Presenting symptoms and signs of duodenal atresia are the result of proximal intestinal obstruction. Duodenal atresia is typically characterized by the onset of vomiting within hours of birth as was seen in our index case. Gastric aspiration volume in a newborn of more than 20 ml is suggestive of intestinal obstruction; normally, aspirates should be minimal [7]. The child in this report had as much as 60 ml of billous aspirate at the initial gastric decompression.

Upright plain abdominal radiograph of the newborns which demonstrate double and distal bowel devoid of intestinal gas have diagnostic values [15]. This is how the diagnosis of duodenal atresia was made in our index patient. (Fig. 1)

When literature series are reviewed, in more than 50% of the cases association of duodenal atresia with Down syndrome, oesophageal atresia, anal atresia and cardiac problems can be seen [4]. The index case has congenital heart disease (congenital mitral incompetence), complete situs inversus abdominalis, intestinal malrotation/volvulus, and polysplenia.

Surgery is the definitive treatment for congenital duodenal atresia. However, adequate intravenous hydration, and gastric decompression are essential until the neonate is stabilized for surgical repair. Dehydration, weight loss and electrolyte imbalance soon follows if fluid and electrolyte losses are not adequately replaced. The patient being discussed had adequate fluid and electrolyte replacement preoperatively.

In patients with duodenal obstruction, a duodeno-duodenostomy is the most commonly performed procedure for operative repair. The patient being discussed in this report had an upper right transverse incision and Kimura diamond duodeno-duodenostomy. He had detorsion of volvulus anticlockwise, ladd bands released, without appendectomy. Also to facilitate postoperative feeding, a transgastric transanastomotic feeding tube was passed. Studies have shown that placing a transanastomotic feeding tube has a beneficial effect on the time to full oral feeding [16]. Our index case was able to attain full oral feeding by the 8th day post-op.

5. CONCLUSION

Duodenal atresia association with situs inversus abdominalis is very rare, a high index of suspicion is necessary particularly when plain radiograph reveals a reverse double bubble sign. Prompt recognition of duodenal atresia with associated situs inversus abdominalis allows for preoperative planning of surgical incision. In the absence of life threatening associated anomalies, the prognosis is good as was in this case.

CONSENT

As per international standard or university standard, patients' written consent has been collected and preserved by the author(s).

ETHICAL APPROVAL

As per international standard or university standard written ethical approval has been collected and preserved by the author(s).

COMPETING INTERESTS

Authors have declared that no competing interests exist.

REFERENCES

1. Piper HG, Alesbury J, Waterford SD, Zurakowski D, Jaksic T. Intestinal atresias: factors affecting clinical outcomes. *J Pediatr Surg.* 2008;43(7):1244-8.
2. Kay S, Yoder S, Rothenberg S. Laparoscopic duodenoduodenostomy in the neonate. *J Pediatr Surg.* 2009;44:906-908.
3. Sharma S, Rashid KA, Dube R, Malik GK, Tandon RK. Congenital duodenal obstruction with *situs inversus totalis*: Report of a rare association and discussion. *J Indian Assoc Pediatr Surg.* 2008;13:77-8.
4. Sweed Y: Duodenal obstruction. In *Newborn surgery* 2nd edition. Edited by Puri P. London: Arnold. 2003;423.
5. Valusek PA, Spilde TL, Tsao K, Peter SDS, Holcomb GW, Ostlie DJ. "Laparoscopic duodenal atresia repair using surgical U-clips: a novel technique," *Surg Endos Inter Techvol.* 2007;21:1023-1024.
6. Brown C, Numanoglu A, Rode H, Sidler D. Situs inversus abdominalis and duodenal atresia: A case report and review of the literature. *S Afr J Surg.* 2009;47:127-30.
7. Intestinal Atresia, Stenosis, and Webs. Available: <https://emedicine.medscape.com/article/940615-overview#a1>. [Accessed 23 February 2022].
8. Ademola OT, Oludayo AS, Adebayo GT, Olusanya A. Situs inversus in association with duodenal atresia. A Case Report. *African J Pediatr Surg.* 2013;10:275-278.
9. Park J, Choe BH, Changs J. Situs Inversus Abdominis Associated with Duodenal Atresia: A Case Report. *J Korean Assoc Pediatr Surg.* 2009;15:52-7.
10. Yasunori T, Masato A, Tadao O, Fumiaki S, Kazutoshi C, Satoshi O. Situs inversus and duodenal atresia. *Hokkaido J Surg.* 2006;51:115-7.
11. Habib Z, Awan M, Kolar M. Laparoscopic duodenoduodenostomy in a newborn with *situs inversus totalis*. *J Laparoendosc Adv Surg Tech A.* 2008;18:654-6.
12. Alatas FS, Masumoto K, Esumi G, Nagata K, Taguchi T. Significance of abnormalities in systems proximal and distal to the obstructed site of duodenal atresia. *J Pediatr Gastroenterol Nutr.* 2012;54(2):242-7.
13. Al-Salem AH. Congenital duodenal obstruction. *Atlas of Pediatric Surgery.* Cham, Switzerland: Springer;2020.
14. Shawis R, Antao B. Prenatal bowel dilatation and the subsequent postnatal management. *Early Hum Dev.* 2006;82:297-303.
15. Qiang S, Fan M, Cui Q, Li Z, Zhou Y, Li Q, Li F. Management of duodenal atresia associated with situs inversus abdominalis: A case report. *Medicine.* 2020;99:31-39.
16. Makkadafi M, Fauzi AR, Wandita S, Makhmudi A, Gunadi. Outcomes and survival of infants with congenital duodenal obstruction following Kimura procedure with post-anastomosis jejunostomy feeding tube. *BMC Gastroenterol.* 2021;21:100-106.

© 2022 Shehu et al.; This is an Open Access article distributed under the terms of the Creative Commons Attribution License (<http://creativecommons.org/licenses/by/4.0>), which permits unrestricted use, distribution, and reproduction in any medium, provided the original work is properly cited.

Peer-review history:

The peer review history for this paper can be accessed here:
<https://www.sdiarticle5.com/review-history/83974>