

See discussions, stats, and author profiles for this publication at: <https://www.researchgate.net/publication/267506324>

Partial Central Retinal Vein Obstruction Combined With Central Retinal Artery Occlusion In A Sickle Cell Disease Patient; A Case Report

Article · August 2014

CITATIONS

0

READS

167

5 authors, including:



Olukorede Adenuga

University of Jos

48 PUBLICATIONS 167 CITATIONS

SEE PROFILE



Ruth Alfin

London School of Hygiene and Tropical Medicine

1 PUBLICATION 0 CITATIONS

SEE PROFILE



Emmanuel Olu Megbelayin

University of Uyo, University of Uyo Teaching Hospital

69 PUBLICATIONS 235 CITATIONS

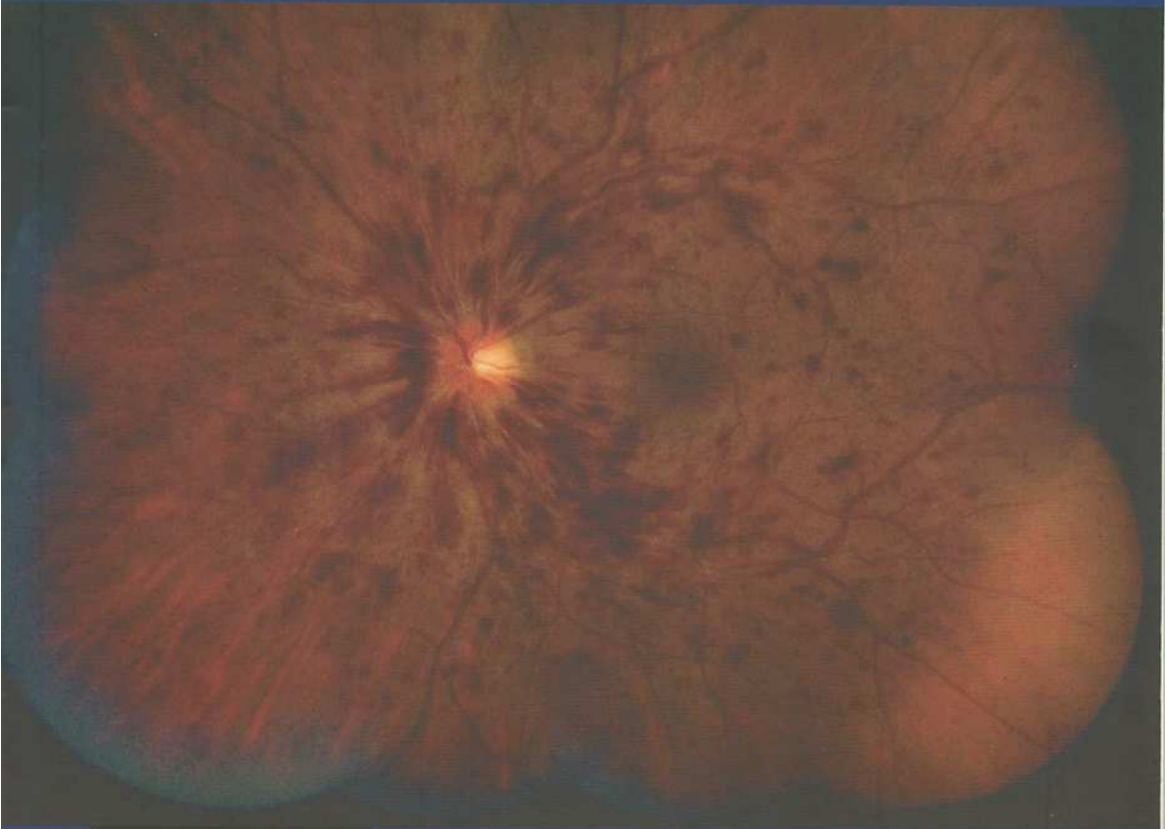SEE PROFILE

VOL. 2, ISSUE NO. 5
SEPT. 14 - JAN. 15

VITREO RETINAL TIMES



A JOURNAL OF THE



ARTICLES BY:

Paul D. Weishaar, MD.
Ehab EL Rayes, MD.
Manish Nagpal, MD.
Olufemi Oderinlo, MD.
Tunji Oluleye, MD.
Olukorede Adenuga, MD.
Imoro Zeba Braimah, MD.
Abdulkadir Rafindadi, MD.
Dung Sunday Nuhu, PharmD

FOCUS ON:

RETINAL VEIN OCCLUSION

Partial Central Retinal Vein Obstruction Combined With Central Retinal Artery Occlusion In A Sickle Cell Disease Patient; A Case Report

Adenuga O.O FWACS, FMCophth¹, **Alada J.J.** MBBS¹, **Alfin R.J.** MBBS¹,

Ureme A.O. MBBS¹, **Megbelayin O.E.** FMCophth²

¹Department of Ophthalmology, Jos University Teaching Hospital, Jos, Plateau State.

²Department of Ophthalmology, University of Uyo, Uyo, Akwa-Ibom State.

Corresponding Author;

Dr. Olukorede O. Adenuga

Department of Ophthalmology,
Jos University Teaching Hospital,
Jos, Plateau State.

E-mail; korexmed@yahoo.com

Phone; +234 8034515042

ABSTRACT

The ocular manifestations of sickle cell disease are diverse and result from vascular occlusion, which may occur in the conjunctiva, iris, retina, and choroid. Occlusion of the central retinal artery or the central retinal vein however occurs rarely. We report a case of a 46 year old known sickle cell disease patient who presented with features of unilateral central retinal artery occlusion and partial central retinal vein occlusion. Occlusion of the central retinal vein and artery occurring simultaneously in a sickle cell disease patient has not been previously documented to the best of our knowledge.

Key Words; central retinal vein occlusion, central retinal artery occlusion, sickle cell disease

INTRODUCTION

Recurrent and unpredictable episodes of vaso-occlusion are the hallmark of sickle cell disease (SCD).¹ Such occlusions may occur in any organ resulting in infarction of tissue in the area distal to the blocked vessel.² The retinal complications of SCD can be non-proliferative or proliferative and these occur as a result of erythrosthiasis secondary to sickling.³ Central retinal vein and central retinal artery occlusion are rare in SCD.^{3,4} The present report describes a patient with homozygous sickle cell (SS)

disease with unilateral extensive retinal oedema and arteriolar attenuation related to a central retinal artery occlusion (CRAO) and retinal signs of a partial central retinal vein occlusion (CRVO).

CASE REPORT

A 46 yr old woman presented with a 3 day history of sudden painless loss of vision in the left eye. The visual loss started from the nasal half of the visual field, involving the temporal half over a period of 24hrs. There was no history of floaters, photopsia or preceding trauma to the eye. She felt her vision had started improving following the pattern in which it was lost as at the time she was being seen. She had an episode of transient loss of vision about 6 months earlier in the same eye with complete recovery of vision within 24hrs. She is a known SCD patient (genotype SS) and had no systemic illness prior to developing the visual loss.

On examination her blood pressure was 120/80mmHg and her pulse rate was 72 beats per minute and was regular. The right eye had a best corrected visual acuity (VA) of 6/6 and the anterior segment was normal. Funduscopy revealed a pink disc with slightly tortuous veins and a flat retina (figure 1). The left eye had a VA of hand movement with a field defect involving the nasal half of the visual field. There was a relative afferent pupillary

defect and examination of the fundus revealed a hyperaemic disc with blurred margins and dilated and very tortuous veins in all four quadrants with perivenular whitening. The retinal arteries were attenuated and there was a peripapillary flame shaped haemorrhage and another small intraretinal haemorrhage superiorly. The entire retina was oedematous but there was no cherry red spot at the macula. No intra-arterial embolus was visualized (figures 2 and 3). A fundus fluorescein angiography could not be done as fluorescein injection was not available in the eye clinic as at the time of reporting this case. The intraocular pressures were 12 and 13mmHg in the right and left eye respectively. A diagnosis of a left partial central retinal vein obstruction combined with central retinal artery occlusion was made on clinical grounds.

Laboratory studies consisting of full blood count, erythrocyte sedimentation rate (ESR), fasting blood sugar and lipid profile were carried out. Her full blood count

result is as follows: haemoglobin 7.4 g/dl, packed cell volume 22%, mean corpuscular haemoglobin concentration 33.6g/dl, mean corpuscular volume 110.4 fl, mean corpuscular haemoglobin 37.2 pg, platelet count $237 \times 10^9/l$, total white cell count $8.7 \times 10^9/l$ and the ESR 15mm/hr. The fasting blood sugar and lipid profile were within normal limits.

Two weeks later, her vision had improved to counting fingers at 2 meters and fundus examination revealed a reduction in the disc hyperemia and retinal oedema. The retinal arterioles had become irregular in caliber, narrow with fractionation of the blood column and the venules were less tortuous. There was a salmon patch haemorrhage close to a retinal arteriole peripherally (figure 4). She was given intravitreal injection of bevacizumab (1.25mg/0.05ml) and her VA improved to 6/60 a week later. Appearance of the fundus was essentially the same as it was before bevacizumab injection.

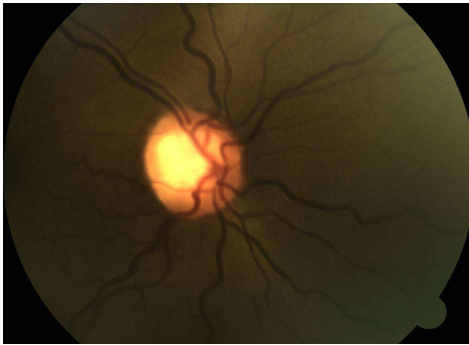

Figure 1

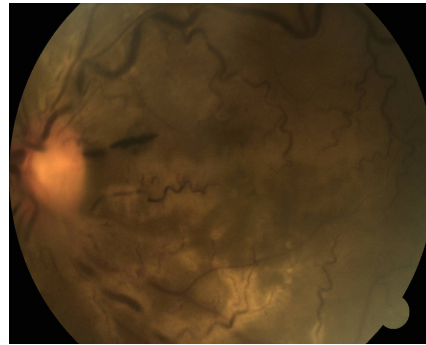


Figure 3

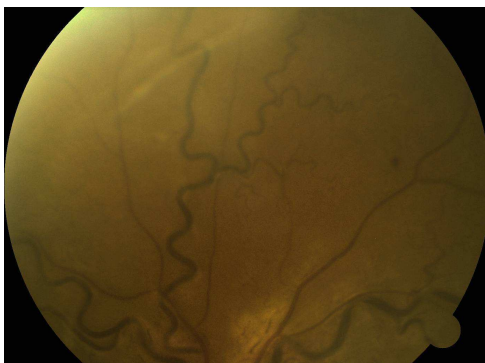


Figure 2

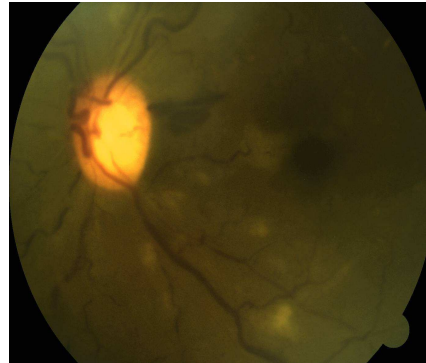


Figure 4

DISCUSSION

Complete occlusions of the central retinal vein and central retinal artery are extremely rare.⁵ There have been several reported systemic and ocular associations of combined retinal arterial and venous occlusion including temporal arteritis, migraine, systemic lupus erythematosus, lupus anticoagulant, syphilis, optic neuritis, and various causes of retinal vasculitis.^{6,7} We did not however come across a reported case in a SCD patient in the literature though few cases of central retinal vein occlusion (CRVO)⁸ and central retinal artery occlusion (CRAO)^{9,10,11} occurring in isolation have been reported in SCD.

Vaso-occlusive events may result in both transient and permanent occlusion of retinal vessels in SCD.¹² Condon *et al*¹² had earlier reported a case of recurrent visual loss in a homozygous SCD patient following transient occlusions of larger retinal vessels. The history of transient visual loss in the same eye in this patient suggests a prior transient vascular occlusion. The features of combined retinal artery and venous occlusion are acute unilateral visual loss with retinal edema (retinal whitening of the posterior pole or along an artery), with or without a cherry red spot on the macula, retinal hemorrhages, enlarged, tortuous veins, delayed arterial dye filling of arteries and prolonged arteriovenous transit time in fluorescein angiography.⁵ If the CRVO is however partial, retinal haemorrhages will be few.¹³ The presence of only two retinal haemorrhages despite the degree of venous tortuosity and engorgement in this patient is in keeping with a partial or impending obstruction of the central retinal vein. Bottós *et al*¹⁴ reported similar fundal features of venous stasis with only a small retinal haemorrhage in a patient with impending CRVO and cilioretinal artery obstruction.

Salmon-patch haemorrhages have been reported following CRAO in sickle cell disease.¹¹ The occurrence in this patient is similar to the case report by Jampol *et al*.¹¹ The development of salmon-patch haemorrhages following retinal artery occlusion in SCD is a delayed phenomenon that tends to occur hours or days after the initial vascular occlusion. Reperfusion of the damaged ischemic vessels

with a blowout of the wall of the vessels seems to be the most likely explanation.¹¹

Vascular occlusion in SCD is as a result of a complex interplay of adhesive events involving sickle red blood cells.¹ Altered erythrocytes can obstruct the vasculature, producing episodes of pain, hemolytic anemia, organ injury, and early mortality.¹ More recent data indicate that other blood cell elements that are not directly affected by the sickle cell mutation play a direct role in vaso-occlusion.¹ Sickle cell patients as a group also have lower levels of the naturally occurring anticoagulants protein S and protein C. This has been attributed to either haemostatic abnormalities or hepatic dysfunction.¹⁵

Studies have shown that treatment of combined central retinal artery and vein occlusion using ophthalmic intra-arterial fibrinolysis with urokinase appears to be beneficial.^{16,17} These studies unfortunately lack a control group and spontaneous improvement in some patients have been reported.¹⁸ The facilities required for this form of treatment is however not readily available in our environment. Intravitreal bevacizumab may also be beneficial in the management of retinal arteriovenous occlusions. Chung *et al*¹⁹ administered intravitreal bevacizumab on 2 patients with central retinal vein occlusion and secondary cilioretinal artery occlusion and suggested that this may improve venous engorgement and retinal hemorrhage, as well as circulation of the cilioretinal artery, thus shortening the disease course. The patients experienced improvements in symptoms within 4-8 weeks. A longer follow-up will be required in this case to determine the outcome of the intravitreal bevacizumab injection.

The prognosis of combined CRAO and CRVO, even if incomplete, is very poor, including blindness if left untreated.⁵ Patients with a combined retinal arteriovenous occlusion should be carefully followed up over months or years because affected eyes tend to develop such complications as rubeosis iridis and neovascular glaucoma.²⁰

REFERENCES

1. Manwani D, Frenette PS. Vaso-occlusion in sickle cell disease: pathophysiology and novel targeted therapies. *Blood* 2013;122:3892–8.
2. Marcus RE, Bolger JP, Roderick PJ, Rowson NJ. Central retinal artery occlusion in homozygous sickle cell (SS) disease. *Clin lab Haemat* 1988;10:467–70.
3. Bonanomi MT, Lavezzo MM. Sickle cell retinopathy: diagnosis and treatment. *Arq Bras Oftalmol* 2013;76:320–7.
4. Hayreh SS, Zimmerman MB, Podhajsky P. Incidence of various types of retinal vein occlusion and their recurrence and demographic characteristics. *Am J Ophthalmol* 1994;117:429–41.
5. Schmidt D. Comorbidities in combined retinal artery and vein occlusions. *Eur J Med Res* 2013;18: 27.
6. Duker JS, Cohen MS, Brown GC, Sergott RC, McNamara JA. Combined branch retinal artery and central retinal vein obstruction. *Retina* 1990;10:105–12.
7. Murray DC, Christopoulou D, Hero M. Combined central retinal vein occlusion and cilioretinal artery occlusion in a patient on hormone replacement therapy. *Br J Ophthalmol* 2000;84:546.
8. Hasan S, Elbedawi M, Castro O, Gladwin M, Palestine A. Central retinal vein occlusion in sickle cell disease. *South Med J* 2004;97:202–4.
9. Liem RI, Calamaras DM, Chhabra MS, Beatrice Files B, Minniti CP, Thompson AA. Sudden onset blindness in sickle cell disease due to retinal artery occlusion. *Pediatr Blood Cancer* 2008;50:624 –7.
10. Fine LC, Petrovic V, Irvine AR, Bhisitkul RB. Spontaneous central retinal artery occlusion in hemoglobin sickle cell disease. *Am J Ophthalmol* 2000;129:680–1.
11. Jampol LM, Condon P, Dizon-Moore R, Serjeant G, Schulman JA. Salmon-patch hemorrhages after central retinal artery occlusion in sickle cell disease. *Arch Ophthalmol* 1981;99:237–40.
12. Condon PI, Whitelocke RAF, Bird AC, Talbot JF, Serjeant GR. Recurrent visual loss in homozygous sickle cell disease. *Br J Ophthalmol* 1985;69:700–6.
13. Kanski JJ, Bowling B. *Clinical Ophthalmology: a systematic approach*. 7th ed. Edinburgh: Elsevier; 2011.
14. Bottós JM, Aggio FB, Dib E, Farah ME. Impending central retinal vein occlusion associated with cilioretinal artery obstruction. *Clin Ophthalmol* 2008;2:665–8.
15. Rahimi Z, Parsian A. 2011. Sickle cell disease and venous thromboembolism *Mediterranean Journal of Hematology and Infectious Diseases* [Online] 3. Available at: <http://www.mjhid.org/article/view/7909> [Accessed 13 June 2014].
16. Vallée JN, Massin P, Aymard A, Paques M, Herbreteau D, Santiago PY, et al. Superselective ophthalmic arterial fibrinolysis with urokinase for recent severe central retinal venous occlusion: initial experience. *Radiology* 2000;216:47–53.
17. Vallée JN, Paques M, Aymard A, Massin P, Santiago PY, Adeleine P, et al. Combined central retinal arterial and venous obstruction: emergency ophthalmic arterial fibrinolysis. *Radiology* 2002;223:351–9.
18. Jorizzo PA, Klein ML, Shults WT, Linn ML. Visual recovery in combined central artery and central vein occlusion. *Am J Ophthalmol* 1987;104:358–63.
19. Chung YC, Chen SJ, Lee SY, Lee FL, Lee SM. Central retinal vein occlusion with secondary cilioretinal artery occlusion treated with intravitreal bevacizumab (Avastin). *Taiwan J Ophthalmol* 2012;2:151-4.
20. Brown JC, Duker JS, Lehman R, Eagle RC Jr. Combined central artery-central vein obstruction. *Int.Ophthalmol* 1993; 17:9–17.