

See discussions, stats, and author profiles for this publication at: <https://www.researchgate.net/publication/372992032>

Evaluation of hepatoprotective activity of the aqueous extract of *Vitis vinifera* against acetaminophen-induced liver damage in rats

Article · August 2023

CITATIONS

0

READS

225

5 authors, including:



Modupe Builders

Bingham University

120 PUBLICATIONS 1,114 CITATIONS

[SEE PROFILE](#)



Oyepata simeon Joseph

Federal University Oye-Ekiti

144 PUBLICATIONS 1,450 CITATIONS

[SEE PROFILE](#)



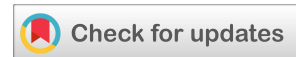Uduak P. Ise

Bingham University Nigeria

23 PUBLICATIONS 32 CITATIONS

[SEE PROFILE](#)

(RESEARCH ARTICLE)



Evaluation of hepatoprotective activity of the aqueous extract of *Vitis vinifera* against acetaminophen-induced liver damage in rats

Modupe Iretiola Builders ^{1,*}, Ifeoma Somtochukwu Okoli ¹, Samuel Otokpa Ede ², Simeon Oyepata Joseph ³ and Peter Uduak Ise ¹

¹ Department of Pharmacology and Toxicology, Faculty of Pharmaceutical Sciences, Bingham University, Karu, Nasarawa State, Nigeria.

² Department of Pharmacology and Toxicology, Faculty of Pharmaceutical Sciences, University of Jos, Plateau State, Nigeria.

³ Department of Pharmacology and Toxicology, Faculty of Pharmacy, Federal University, Oye-Ekiti, Ekiti State, Nigeria.

Magna Scientia Advanced Research and Reviews, 2023, 08(02), 104–110

Publication history: Received on 25 May 2023; revised on 21 July 2023; accepted on 24 July 2023

Article DOI: <https://doi.org/10.30574/msarr.2023.8.2.0096>

Abstract

In this study we evaluated the hepatotoxicity activity of *Vitis vinifera* in acetaminophen induced liver damage in rats. Five (5) Groups of rats were used for the study, Group 1 received normal saline (1ml /kg, p.o), Group II received acetaminophen (300mg/kg, i.p), Group III received (300mg/kg, i.p) acetaminophen and (150mg/kg, o.p) *Vitis vinifera* juice, Group IV received (600mg/kg, i.p) acetaminophen and (300mg/kg, o.p) *Vitis vinifera* juice while Group V received (600mg/kg, i.p) acetaminophen and Silymarin (25mg/kg, o.p) simultaneously once daily for four (4) days. Acute toxicity study and histopathological analysis were carried out. The LD₅₀ was found to greater than 4000mg/kg body weight. The aqueous extract of *Vitis vinifera* significantly ($P < 0.05^*$) reduced the hepatic enzymes from aspartase transaminase (AST) ($415 \pm 0.2^*$ to $94.5 \pm 0.8^*$) alanine transaminase (ALT) ($132 \pm 2.2^*$ to $60.5 \pm 0.2^*$) and alkaline phosphase ALP ($118 \pm 0.6^*$ to $87.5 \pm 2.1^*$) while there were no significant changes in the total bilirubin (TB) and direct bilirubin levels comparable to the reference drug. These findings confirm the histopathology study which indicated no adverse effects on the liver. The aqueous extract of the *Vitis vinifera* possesses hepatoprotective activity against acetaminophen induced liver damage, therefore further studies should be carried out to determine the exact mechanism of action as well as phytochemicals responsible for these activities.

Keyword: *Vitis vinifera*; Acetaminophen; Hepatotoxicity; Hepatic enzymes; Histopathological study

1. Introduction

Herbal drugs are prescribed widely because of easy accessibility, acceptability, effectiveness and fewer side effects as well as relatively low cost [1]. However, a potent therapeutic for serious liver diseases is still unknown, therefore, there is need for effective and safe drugs for liver disorders. Today, there has been a global trend for the revival of interest in the traditional system of medicine. The most popular ayurvedic herbal preparation Liv.52 by Himalaya Drug Company is widely used for the treatment of various liver diseases. The scientific investigation or evaluation of medicinal plants has become more essential today [2].

Vitis vinifera Linn. (Commonly known as Grape Vine) (Vitaceae), which is commonly known as grape is an erect shrub with woody vine comprising of tendrils (modified branches). Ethnomedicinally, different parts of the plant are used for the treatment of various diseases such as malaria, bacterial infection, fungal infection, cancer, liver disease, diarrhea, constipation and cardiovascular diseases [3, 4].

* Corresponding author: Modupe Iretiola Builders

Liver disease is one of the most common health problem, the disease may be caused by either viral infection or drug induced. Inherited diseases such as Wilson disease and hemochromatosis are also indicated in liver disease. In the most severe cases, drug-induced liver disease can require liver transplantation or lead to the death and can also lead to the withdrawal of causative drug from the market or earlier during clinical trials, thus causing huge financial losses [5].

Several studies have shown that the most commonly used analgesic is acetaminophen (paracetamol), acetaminophen is used for mild pain, fever, as an alternative for aspirin and lacks anti-inflammatory activity. Unlike Non-Steroidal Anti-inflammatory Drugs (NSAIDS), acetaminophen does not cause gastrointestinal tract irritation but characterized by both acute toxicity and chronic toxicity [6].

Paracetamol undergoes metabolism through an alternative pathway to form a toxic metabolite N-acetyl-p-benzoquinone imine(NABQI), which displaces the natural antioxidant (glutathione) from the liver. Excess NABQI causes necrosis of the liver and renal tubules leading to liver damage [7].

In spite of high advances in modern medicine, there are no completely effective drugs that stimulate hepatic function, that offer complete protection of the organ, or that help to regenerate hepatic cells. It is necessary to identify pharmaceutical alternatives for the treatment of liver diseases, with the aim of these alternatives being more effective and less toxic. The aim of this study is to investigate the protective effects of grape and its phytochemicals on the liver of acetaminophen-induced rats.

2. Material and methods

2.1. Drugs and chemicals

Acetaminophen (Drugfield Pharmaceuticals Ltd, Nigeria), Silymarin (Micro Labs, India), Normal saline (Fidson Healthcare Plc, Nigeria). All other chemicals used in the study were of analytical grades.

2.2. Collection and extraction of the plant material

Fresh, ripe fruits of *Vitis vinifera* were purchased from Garki, Abuja and identified by a taxonomist in the Department of Medicinal Plant Research and Traditional Medicine, National Institute of Pharmaceutical Research and Development, Abuja, Nigeria. The fruits were grinded using a blender, and the juice was extracted manually using a muslin cloth. The manually extracted juice was freeze dried using a freeze dryer at -62°C for 72hours. The yield was found to be 10g/kg.

2.3. Experimental animals

Wistar rats weighing between 150 g and 200 g were purchased from the Bingham University Animal House. They were housed in clean propylene cages and fed with standard rodent pellets and water was provided *ad libitum*.

2.4. Acute toxicity study

Acute toxicity studies were performed according to OECD-423 guidelines [8]. Mice were selected by random sampling technique and the animals were fasted for 1 hour with free access to water only. *Vitis vinifera* juice extract was administered orally at a dose of 20 mg/kg initially and mortality observed for 3 days. The dose administered was considered as toxic dose if mortality was observed in two out of three animals. If the mortality was in only one animal out of three animals, then the same dose was repeated again to confirm the toxic effect. The higher (100, 500, 4000 mg/kg) doses of *Vitis vinifera* juice extract were adopted for further toxicity studies if no mortality was noticed.

All the doses (20, 100, 500 and 4000 mg/kg) of *Vitis vinifera* juice extract employed for acute oral toxicity studies were found to be non-toxic. *Vitis vinifera* juice extract did not produce any mortality even at the highest dose (4000 mg/kg) employed. Two sub maximal doses (150 and 300 mg/kg), which were found to be safe and were selected for further pharmacological investigations.

2.5. Experimental design

The animals were divided into 5 Groups of 5 animals each. Group I, which served as normal control, received normal saline (1 ml/kg, p.o.); Group II received Acetaminophen injection (600mg/kg, i.p.) (17) once daily for 4 days. Group III received Acetaminophen (600mg/kg, i.p.) and *Vitis vinifera* juice extract (150 mg/kg, p.o.) simultaneously once daily for 4 days. Group IV received Acetaminophen (600mg/kg, i.p.) and *Vitis vinifera* juice extract (300 mg/kg, p.o.)

simultaneously once daily for 4 days. Group V served as standard Group and Acetaminophen (600mg/kg, i.p.) and Silymarin (25 mg/kg, p.o.) simultaneously once daily for 4 days.

All animals were prevented from feeding for 24 hours after administration, before being sacrificed for assessment of liver histology, as well as serum biochemical marker enzymes [9].

2.6. Assessment of serum hepatic biomarkers

At 24 hours' post-administration, on the 5th day, experimental rats were anaesthetized by putting each one in a glass jar containing ethanol-soaked cotton wool for about 30seconds. Blood was obtained through cardiac puncture, through a heparinized capillary tube into a sample bottle. Each sample was centrifuged at 2500 rpm at 37°C for 20 min to separate serum.

Samples were analyzed for hepatic enzymes such as alkaline phosphatase (ALP), alanine aminotransferase (ALT), aspartate aminotransferase (AST), and direct bilirubin (DB) level as well as total bilirubin (TB) level using commercially available kits [9].

2.7. Collection of liver for histological assay

After blood collection through the cardiac puncture, a deep longitudinal incision was made into the ventral surface of each rat abdomen. The livers were identified and carefully dissected out from two rats of each Group and washed with normal saline. The livers of the rats of all Groups were excised from the animals and washed with the normal saline. The materials were fixed in 10% buffered neutral formalin for 48 h and then with bovine solution for 6 h and processed for paraffin embedding. Sections of 5 m thickness were taken using a microtome, processed in alcohol-xylene series and were stained with alum-hematoxylin and eosin and subjected to histopathological examination [10].

3. Results and discussion

3.1. Biochemical estimation

The result of hepatoprotective potential of *Vitis vinifera* juice extract on Acetaminophen-treated rats is shown in Table. 1 below. The *Vitis vinifera* juice extract treated Group (150 mg/kg) have minor effect on the levels of hepatic enzymes when compared to Acetaminophen-treated animals. The *Vitis vinifera* juice extract treated Group (300 mg/kg) significantly reversed the levels of hepatic enzymes when compared to Acetaminophen-treated animals. Silymarin (25 mg/kg)-treated animals also showed significant reduced levels of hepatic enzymes when compared to Acetaminophen-treated animals. There was a significant decrease in the serum of biochemical marker enzymes (AST, ALT and alkaline phosphatase (ALP)). The aqueous extract of *Vitis vinifera* indicated no significant change in the levels of both direct bilirubin (DB) and total bilirubin (TB).

Table 1 Effect of aqueous extract of *Vitis vinifera* on some serum biochemical parameters of Acetaminophen (ACM) intoxicated rats. Data expressed as mean± SEM $p < 0.05^*$ is considered significant

TREATMENT	AST (U/L)	ALT (U/L)	ALP (U/L)	TB ($\mu\text{mol/L}$)	DB ($\mu\text{mol/L}$)
CONTROL	364.4±1.1	73.0±1.4	109.0±2.1	3±0.1	2±0.1
GROUP 2	415.0±2.0*	132±2.2*	118±0.6*	3±0.1	2±0.1
GROUP 3	400.0±0.2	243.6±1.2	128.8±0.2	3±0.1	2±0.1
GROUP 4	94.5±0.8*	60.5±0.2*	87.5±2.1*	3±0.1	2±0.1
GROUP 5	225.2±1.2*	21.4±0.4*	196.8±0.7	3.2±0.2	3.4±0.1

3.2. Treatment

- Group I (Control Group): Normal saline (1ml/kg)
- Group II (Negative control): Acetaminophen (600mg/kg)
- Group III: Acetaminophen (600mg/kg, i.p) + *Vitis vinifera* juice extract (150mg/kg)
- Group IV: Acetaminophen (600mg/kg, i.p) + *Vitis vinifera* juice extract (300mg/kg)
- Group V: Acetaminophen (600mg/kg, i.p) + Silymarin (25mg/kg)

3.3. Histopathological study

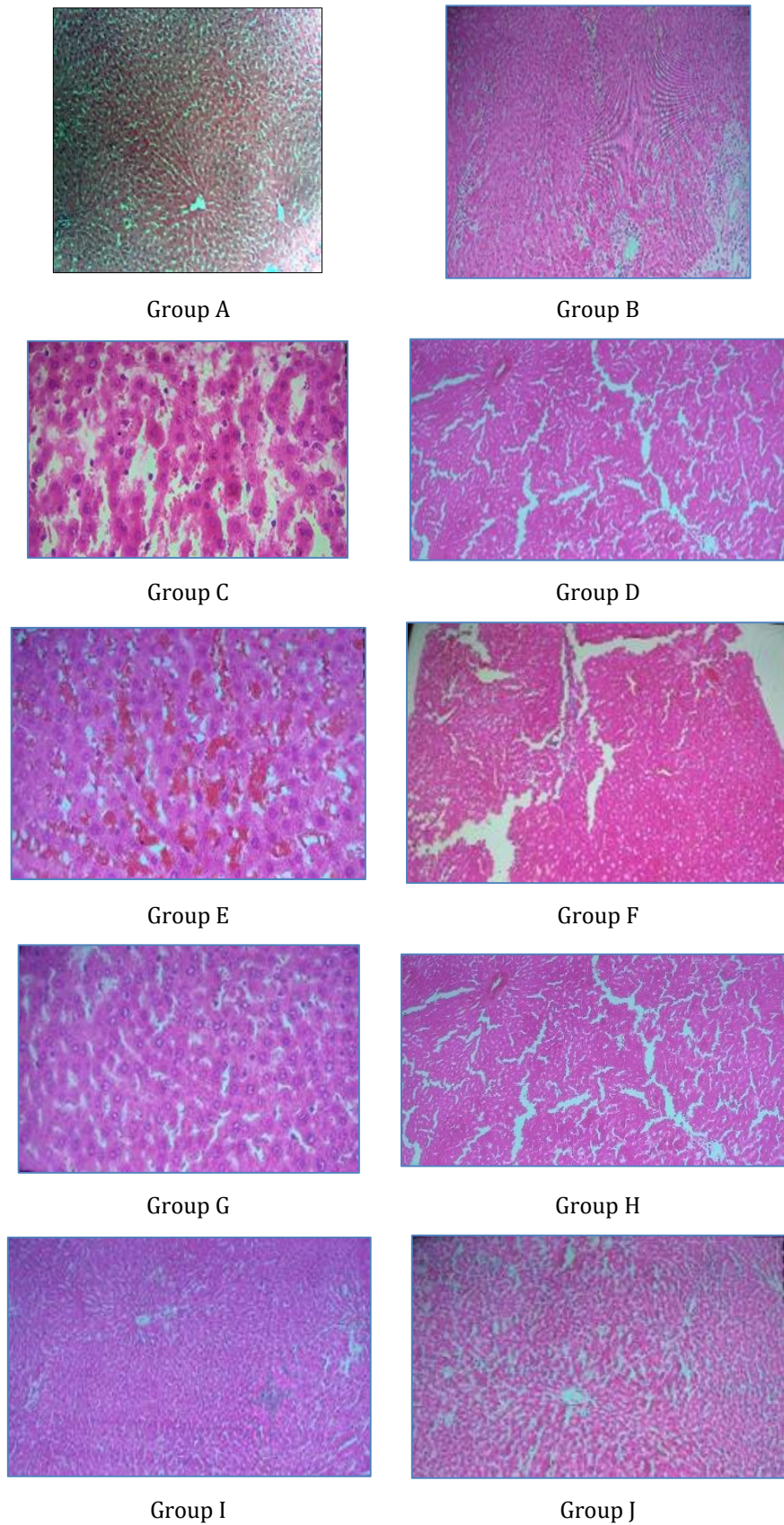


Figure 1 Photomicrographs of the normal and treated rats

3.4. Photomicrographs of the normal and treated rats

3.4.1. Group A

Photomicrograph of the normal liver of Wistar rat from Group Male (Control). Showing normal Central Vein , Hepatocytes and Sinusoids . (H&E X100)

3.4.2. Group B

Photomicrograph of the normal liver of Wistar rat from female (Control). Showing normal Central Vein , Hepatocytes and Sinusoids (H&E X100)

3.4.3. Group C

Photomicrograph of the liver of Male Wistar rat administered with 600mg/kg acetaminophen showing extensive hepatocellular damage with the presence of centrilobular necrosis (H&E X100)

3.4.4. Group D

Photomicrograph of the liver of female Wistar rat administered with 600mg/kg acetaminophen showing extensive hepatocellular damage with the presence of centrilobular necrosis and constricted blood vessel (H&E X100)

3.4.5. Group E

Photomicrograph of the liver of male Wistar rat administered with 600mg/kg acetaminophen with *Vitis vinifera* 150mg/kg showing mild hepatocellular damage with scanty hepatocytes. (H&E X100)

3.4.6. Group F

Photomicrograph of the liver of female Wistar rat administered with 600mg/kg acetaminophen with *Vitis vinifera* 150mg/kg showing mild hepatocellular damage with scanty hepatocytes. Constricted blood vessel and inflammation of the vessels cell wall distorted (H&E X100)

3.4.7. Group G

Photomicrograph of the liver of male Wistar rat administered with 600mg/kg acetaminophen with *Vitis vinifera* 300mg/kg showing reduced hepatocellular damage with restored histological structure (H&E X100)

3.4.8. Group H

Photomicrograph of the liver of female Wistar rat administered with 600mg/kg acetaminophen with *Vitis venifera* 300mg/kg showing hepatocellular damage with mild inflammation of blood vessel gradual restoration (H&E X100)

3.4.9. Group I

Photomicrograph of the liver of male Wistar rat administered with 600mg/kg acetaminophen with 25mg/kg of Silymarin showing reduced normal histological structure of the liver with Clouded Central Vein with centralize hepatocytes within the sinusoid (H&E X100)

3.4.10. Group J

Photomicrograph of the liver of female Wistar rat administered with 600mg/kg acetaminophen with 25mg/kg of Silymarin showing reduced hemorrhage with the blood vessel well defined histological structure seen. Hepatocytes and sinusoid (H&E X100).

Acetaminophen is a popularly used analgesic drug which causes severe hepatic damage when taken in high doses. The assessment of liver function can be made by estimating the activities of serum enzymes such as AST, ALT and ALP. During hepatic damage, there may be an increase in these enzyme levels in serum with the extent of liver damage. The altered levels of these enzymes in Acetaminophen-treated rats in the present study corresponded to the extensive liver damage induced by the toxins [11].

The present study has demonstrated that *Vitis vinifera* juice extract at 300 mg/kg exhibited significant hepatoprotective activity against liver injury induced by Acetaminophen. Acetaminophen induces hepatotoxicity through formation of the noxious NAPQI metabolite, which is present in excessive quantities, as augmented by features of glutathione (GSH)

depletion, oxidative stress and mitochondrial dysfunction leading to depletion in adenosine triphosphate (ATP) stores [5].

Increase in serum level of ALP in the Acetaminophen induced liver damage Group is due to increased synthesis, in the presence of increasing biliary pressure and reflects the pathological alteration in biliary flow [10]. Therefore, reduction in level of ALP in the treated rats provides a valuable indication that the plant may be useful in treatment and prevention of conditions such as of gallstone and cholecystitis [5]. Acetaminophen-induced toxicity in rats may have altered membrane structure and function as well as lipids metabolism in the liver. Alteration of bio-membrane lipid profile disturbs its fluidity, permeability, activity of associated enzymes and transport system and this could affect lipid transport in the liver [9].

Several medicinal plants have been found to inhibit xenobiotic induced hepatotoxicity as well as nephrotoxicity due to their potent anti-oxidant or free radical scavenging effects [11, 12].

The juice extract of grapes has been shown to contain many active components such as phenolic acids, stilbenes, anthocyanins, and proanthocyanidins, organic acids, flavonols, tannins, procyanidins, enzymes, vitamins, and carotenoids [13], that can increase the total antioxidant power in blood and reduce lipid peroxidation level. The liver protective activity elicited by the extract might be due to its ability to activate antioxidant enzymes suppressed by ACM-induced toxicity [14, 15].

The histological examination of the liver tissues indicated that rats treated with *Vitis vinifera* (300mg/kg) had significantly reduced hepatocellular damage when compared to rats treated with Acetaminophen (600mg/kg) alone. The effects of *Vitis vinifera* juice extract (300mg/kg) were comparable with the effects of the silymarin-treated Group.

4. Conclusion

It can be concluded that the juice of *Vitis vinifera* fruit possesses hepatoprotective activity against Acetaminophen-induced liver damage in rats. According to the results obtained in this study, it may be inferred that, in general, *Vitis vinifera* juice extract reverses the hepatic damage induced by Acetaminophen. Validation scientific work on *Vitis vinifera* is scanty, this is the first report about *in vivo* activity of *Vitis vinifera* fruit and it seems to raise some concern about the traditional indications of this species as a medicine for liver diseases. Certainly, further studies need to be carried out with other hepatotoxic compounds to prove the hepatoprotective efficacy of *Vitis vinifera*.

Compliance with ethical standards

Acknowledgement

The authors are grateful Oluwakemisola Akingbade for the payment of publication fee

Disclosure of conflict of interest

No conflict of interest to be disclosed.

Statement of Ethical approval

Approval for this study was sought ethically from Bingham University Research Ethics Committee

References

- [1] Builders MI, Builders PF, Ogundeko TG. Anti-ulcer activity of the stem bark of African locust bean tree in Rats. *Int J Phytoter Res.* 2016; 6 (4): 11-8.
- [2] Sato A. Revealing the popularity of traditional medicine in light of multiple recourses and outcome measurements from a user's perspective in Ghana. *Health Policy and Planning.* 2012; 27: 625–37.
- [3] Klunen MA, Xu X, Yang Q, Maurel N, Zhang Z et al. Economic use of plants is key to naturalization success. *Nature Communications.* 2020; 11 (3201): 12
- [4] Liu J, Wang Y, Yu Z, Lv G, Huang X. Functional mechanism of Ginsenoside Compound K on tumour growth and metastasis. *Integrative Cancer Therapies.* 2022; 21(1-3): 13.

- [5] Sabastine AZ, Musa TL, Joseph OS, Builders M, Joseph OS. Histological Study of Effect of Ethanol Stem Extracts of *Homalium Letestui* in Paracetamol Induced Injury in Albino Rat, Using Various Staining Techniques. *American J Biomed Sci Res.* 2019; 4(2): 82-7.
- [6] Builders MI, Bassi PU. Assessment of analgesic usage among the patients in Bingham University Teaching Hospital. *Int J Med Biomed Res.* 2017; 6(2):92-8.
- [7] Golar SK. Use and understanding of analgesics (painkillers) by Aston university students. *Biosci Horizon* 2011; 4:71-7.
- [8] Ecobichon DJ. *The basis of toxicology testing.* IST Edition. New York: CRC Press, 1997. p.43.
- [9] Builders IM, Joseph OS, Joseph OT. Toxicological study of ethanol extract of *Lavandula stoechas* on Liver of Wistar rat. *Int J Adv Eng Mgt (IJAEM).* 2022; 4 (9): 892-9.
- [10] Wazis CH, Builders M, Joseph OS, Joseph OT. Toxicological Study of the Effect of Ethanol Leaf Extract of *Pterocarpus santalinus* Extract on Liver of Wister Rats. *Nig Biomed Sci J.* 2020; 17 (1): 20-11.
- [11] Munoz-Reyes D, Casanova AG, Gonzalez-Paramas AM, Martin A, Santos –Buelga C. Protective effect of quercetin - 3-O-Glucuronide against Cisplatin cytotoxicity in renal tubular cells. *Molecules.* 2022; 27 (1319): 18.
- [12] Meena V, Baruah H, Parveen R. *Cassia auriculata*: A healing herb for remedy. *J Pharmacognosy and Phytochemistry.* 2019; 8(3): 4.
- [13] Raja WD, Amit VP. Evaluation of Phytochemicals Screening and Antioxidant Activity of *Vitis vinifera* (Grapes) Fruit Extract using Fenton Reaction. *Eur J Pharmaceut Sci.* 2020; 7. 582-5.
- [14] Silvagno F, Vernone A, Pescarmona GP. The role of glutathione in protecting against severe inflammatory response triggered by COVID-19. *Antioxidants.* 2020; 9(624): 15.
- [15] Boro H, Usha T, Babu D, Chandana G, Goyal AK et al. Hepatoprotective activity of ethanolic extract of *Morus indica* roots from Indian Bodo tribes. *SN Applied Sciences.* 2022; 4: 49.